



Digitized by the Internet Archive
in 2015

<https://archive.org/details/b21303228>

200955019 7

S/Ns 610420



KING'S COLLEGE LONDON

H. Wilton by Tyler
1898.

KING'S
College
LONDON

KCSM: POL. RC 333 YEO

Library

YEO, FRANCIS FRANK
A RECORD OF EXPERIMENTS
1874



A RECORD OF EXPERIMENTS

ON THE

EFFECTS OF LESION OF DIFFERENT REGIONS

OF THE

CEREBRAL HEMISPHERES.

BY

DAVID FERRIER, M.D., LL.D., F.R.S.,

PROFESSOR OF FORENSIC MEDICINE IN KING'S COLLEGE,

AND

GERALD F. YEO, M.D., F.R.C.S.,

PROFESSOR OF PHYSIOLOGY IN KING'S COLLEGE, LONDON.

From the PHILOSOPHICAL TRANSACTIONS OF THE ROYAL SOCIETY.—PART II. 1884.

610446
KCSM

LONDON:
HARRISON AND SONS, PRINTERS IN ORDINARY TO HER MAJESTY,
ST. MARTIN'S LANE.

3917.
4-8-1953



Presented by
Dr. Willoughby hyle.

XIX. *A record of Experiments on the Effects of Lesion of Different Regions of the Cerebral Hemispheres.*

By DAVID FERRIER, M.D., LL.D., F.R.S., Professor of Forensic Medicine in King's College, and GERALD F. YEO, M.D., F.R.C.S., Professor of Physiology in King's College, London.

Received January 19,—Read January 24, 1884.

[PLATES 20-36.]

PREFATORY NOTE.

THE facts recorded in this paper are partly the results of a research made conjointly by Drs. FERRIER and YEO, aided by a grant from the British Medical Association, and partly of a research made by Dr. FERRIER alone, aided by a grant from the Royal Society.

It has been considered convenient and advisable to publish the results together, more especially with the view of contrasting the different effects of lesions of different parts of the brain established under similar conditions.

The conjoint experiments are distinguished by an asterisk. Of these alone joint authorship is to be understood. A preliminary account of some of these has already been given by the authors:—at the meeting of the British Medical Association at Cambridge in 1880, and at the International Medical Congress in London in 1881. The experiments are here related in detail.

The number of illustrations which accompany the paper is large, but this is considered necessary, as the text is mainly a short description and simple comment on the effects of the lesions delineated.

The illustrations have for the most part been executed by Dr. FERRIER, and consist of photographs taken, with few exceptions, direct from the brains after hardening in spirit or bichromate solution, and of sun-prints [direct from the sections used as negatives], and microphotographs of sections made by him.

The authors here desire to express their grateful thanks to Mr. J. M. THOMSON, Demonstrator of Chemistry in King's College, for much assistance in photography, and to Messrs. GROVES and BROOKS, Demonstrators of Physiology in King's College, and to their pupils Messrs. EAST, LE MAISTRE, NORVILL, PORTER, TURNER, and others for valuable aid rendered in various ways and at different periods in the course of the investigations.

INTRODUCTION.

The subjects of the following experiments were exclusively Monkeys, mostly species of Macacque.

The animals were in all cases thoroughly narcotised with chloroform, and kept in a state of complete anæsthesia during the whole of the operative procedure.

The lesions were made as a rule by means of the galvanic cautery. Occasionally the ordinary cautery was employed where the other was inconvenient.

All the operations were carried out under antiseptic precautions. These and the modes of dressing the wounds have been described by the authors elsewhere and are not entered into here.

SECTION I.

LESIONS OF THE ANGULAR GYRI AND OCCIPITAL LOBES.

*Experiment 1** (Plate 20, fig. 1).

In this animal the *left occipital lobe* was exposed and entirely severed and removed in a line parallel with, and $\frac{3}{16}$ ths of an inch posterior to, the parieto-occipital fissure. The left eye was bandaged, and the animal left to recover from its stupor.

An hour after the operation it was able to sit up, but it was very prostrate, and unwilling to move.

Next morning it was found to have torn off all the dressings, and the wound was discharging freely. The animal was however very lively and ate heartily. No affection of vision could be made out. It thrust its hands through the bars of the cage to lay hold of things offered it, and it did so with its right hand to seize a piece of potato held to its right front. There seemed therefore to be no right hemiopia.

Some hours afterwards the animal was allowed to run about the laboratory, which it did in every direction, passing among chairs, tables, and other articles of furniture without ever once knocking its head on one side or the other.

A slight degree of awkwardness was observed at this time in the movements of the right hind leg, which had not been observed before.

Nothing else of importance was noted during the next two days except an increase in the weakness of the right leg. There were signs of inflammation and hernia cerebri, and the animal became comatose and died on the fifth day after the operation.

Post-mortem examination—The edges of the incision of the scalp had not united, and at the posterior extremity a portion of reddish fungus cerebri was protruding. On removal of the scalp the opening in the left occipital region was found to be filled with a protruding fungus, and on removal of the dura mater the whole convexity of the left hemisphere was seen to be intensely congested. A less degree of vascularity also existed on the right side.

There was some degree of congestion and exudation also at the base.

The margin of the fungus cerebri of the left hemisphere, which bulged considerably above the level of the rest of the tissue, corresponded very closely with the position of the parieto-occipital fissure, the posterior limb of the angular gyrus merging gradually into it (see Plate 20, fig. 1).

The posterior angle of the postero-parietal lobule formed part of the fungus.

Remarks.—This, the first of the series, was an unsuccessful experiment as regards antiseptics, owing to the dressings not having been fixed in such a manner as to prevent their being torn off by the animal. Owing to this, though the dressings were re-applied, and the wound was treated on the most approved surgical principles, meningo-encephalitis and death occurred.

The case however shows that, notwithstanding the almost entire removal of one occipital lobe, vision was not appreciably affected; inasmuch as the animal was able to run about and avoid all obstacles on either side, and also to pick up things on either side, and with either hand: actions which would not be consistent with the existence of hemiopia on one side or the other.

The weakness of the right leg can be accounted for by the implication of the cortex and medullary fibres of the postero-parietal lobule in the inflammatory softening of the fungus cerebri.

*Experiment 2** (Plate 20, figs. 2 and 3).

In this animal—a small Baboon—*both occipital lobes* were exposed by a trephine opening in each occipital region $\frac{3}{4}$ inch in diameter. With the galvanic cautery a deep incision was made in each occipital lobe at right angles to the longitudinal axis, the cortex and medullary fibres being broken up and disorganised so far as the trephine openings permitted, to the depth of an inch or more so far as could be judged.

Within an hour the animal was able to run about the laboratory, and being near some hot pipes, it stretched out its hands, seized the top pipe, and climbed up.

Within two hours it was quite lively and active, responded when whistled to, and took things offered it without hesitation.

Two hours and a quarter after the operation the animal, which had been sitting on a ledge—to which it had climbed—eating a potato, jumped down after finishing it, and took possession of another piece which had been laid on the table some time previously.

There was therefore no question as to the animal's vision.

Next day the animal was in all respects normal, active and vivacious, curious as to all within its reach, and very expert in catching flies buzzing about. It showed signs of liking the smell of bergamot, made grimaces over acetic acid, and spat out a piece of potato which had been smeared with aloes. Motor powers and tactile sensibility were unimpaired.

This animal continued in perfect health, and was noted for its fun and tricks, and domineering over all its companions.

Six months after the operation on the occipital lobes, the *prefrontal regions* were similarly exposed and broken up with the galvanic cautery—the lesions being made, so far as could be determined, in the region of the middle frontal convolution anterior to the antero-parietal or pre-central sulcus.

In less than an hour the animal began to move about, though in a somewhat sleepy and listless manner.

An hour and a half after the operation it was able to walk about quite well, and took a piece of apple offered it. Left to itself it shut its eyes and seemed asleep, but if called to it opened its eyes momentarily, but subsided again.

An hour subsequently it still maintained the same dull and listless attitude, though when called to it would brighten up for a moment. It jumped down eagerly to seize a piece of apple thrown into its cage, but having got it, remounted its perch and went to sleep holding the apple in its hand.

Next day the condition was much the same. The animal would wander about vacantly, or occupy itself picking among the rubbish in its cage.

Watched from day to day, it exhibited no defect as regards any of its movements, ocular or otherwise, or as regards any of its sensory faculties, which were tested in various ways. Only its manner seemed changed, and this was noted by all who had seen its former vivacity. It lost all its fun and trickiness, seemed not to know its name, took little or no interest in its companions, and was very easily cowed by them. Its physical health was excellent, and it enjoyed its food heartily. Psychically only it had undergone appreciable change and degradation.

In this condition it continued for the next three months, when it was killed with chloroform.

Post-mortem examination.—The brain was everywhere normal, except in the prefrontal and occipital regions corresponding to the openings in the cranium above described. These were covered by membrane continuous with the dura mater and adherent to the brain beneath.

The occipital lobes were each the seat of a depression and loss of substance, the cicatrices of the destructive lesions inflicted on them (see Plate 20, fig. 2). These were almost symmetrical and occupied the convexity of each occipital lobe about a centimetre in extent and depth, parallel, and $\frac{1}{4}$ inch posterior to the parieto-occipital fissure.

In each prefrontal lobe there was a more or less circular cicatrix, somewhat larger on the right than left, and measuring $\cdot 5 - \cdot 75$ centimetre in diameter, the centre of which appeared to correspond with the middle of the middle frontal convolution. But there was an evident distortion of the convolutions which seemed to be caused by a contraction towards the centre of the cicatrices, and this to such an extent as to tilt the orbital surface upwards and forwards. This condition is seen in the photograph, where the slight shadow indicates the orbital aspect of the frontal lobes. The cicatrices, which sunk to a depth of half a centimetre or more (Plate 20, fig. 2), measured

half a centimetre in diameter—more on the right than left—instead of three-quarters of an inch, the original extent of the lesion. The greater portion of the middle and inferior frontal convolutions had been destroyed.

The caudate nuclei were uninjured, as also the rest of the brain.

Remarks.—This case shows that lesions may be made simultaneously in both occipital lobes without any perceptible impairment of vision, or other defect. Notwithstanding the subsequent considerable destruction of the cortex in both prefrontal regions, there was no perceptible physiological defect either as regards motion or sensation, general or special.

Further observations on the effects of lesions of the prefrontal regions will be found detailed in Section IV. In this case a psychological alteration was very evident but difficult to define, shown more particularly in listless apathy, contrasting strongly with the previous vivacity and active curiosity which characterised the animal.

*Experiment 3** (Plate 20, fig. 4).

In this case the *right angular gyrus* was exposed, and the cortical matter of the convexity of both limbs was destroyed by the galvanic cautery.

After the narcotic stupor had passed off, the eyes were observed to be both widely open, the pupils small and equal, and the conjunctival reflex equally distinct on both sides.

Both eyes were left open and the animal left to itself. For an hour it seemed quite disinclined for exertion, but at the end of this time began to move about, occasionally replying to grunts from its companions.

A quarter of an hour afterwards it put out its hand to take a piece of apple offered it, but seemed to be uncertain as to the exact position and distance.

An hour after this the right eye was bandaged. The animal seemed then very unwilling to move, and when it did, knocked its head on several occasions against some obstacle, and sat down. When placed in its cage it would do nothing but lie down. After this had been observed for a quarter of an hour the bandage was removed from the right eye, whereupon the animal began to look about, and though it would not run about the laboratory very freely, when placed in its cage it at once jumped on to a hot-water pipe which ran along the back of its cage and remained there.

Next day the animal seemed perfectly well, and took things offered it with the utmost precision.

The right eye was then bandaged, but though the animal seemed to dislike the bandage, and would not run about spontaneously, it did so when urged, and showed no signs of impairment of vision, passing obstacles on every side without hesitation or knocking its head. It was able also to lay hold of things offered it on either side.

Similar observations were made on the following day, and with precisely the same results.

On the next day the left eye was bandaged, but there was no sign of impairment of vision in the right eye.

The animal died eighteen days after the operation, the weather being intensely cold, and the temperature of the laboratory having sunk very low, from defect in the heating arrangements at the time.

Post-mortem examination.—The scalp wound was healed, and there were no signs of hernia cerebri or inflammation.

The brain was injured by the saw during removal, as seen in the photograph (Plate 20, fig. 4).

The brain was everywhere normal except in the region of the *right angular gyrus*. This, as seen in the photograph, had the cortical substance eroded and disorganised over the convex aspect of both limbs. The depth of the lesion was comparatively slight, and the grey matter of the sulci separating the angular gyrus from the adjoining convolutions was not injured. A thin strip of uninjured cortical substance formed the posterior boundary of the intraparietal sulcus.

Remarks.—In this case of unilateral lesion, not amounting to entire destruction of the angular gyrus, there was a temporary impairment of vision, after the animal had otherwise entirely recovered its other faculties and powers.

At first, when both eyes were open, the defect was shown in inability to realise the exact position of objects. But when the right eye was closed, it was seen that vision was specially defective, if not for a time entirely abolished, on the side opposite the lesion.

Next day no defect could be ascertained, either amblyopic or hemiopic, and the animal was in all respects apparently perfectly normal.

*Experiment 4** (Plate 20, figs. 5 and 6).

In this animal the *left angular gyrus* was exposed and cauterised on the convexity so as to destroy the grey matter of the two limbs of this convolution. By the time the dressings were applied the animal was awake, keeping both eyes open, and looking about. The left eye was then securely closed, and the animal left to itself. After a few minutes it got up and began to sprawl about in its cage, knocking its head in every direction.

Being let out it walked straight on and came full tilt with its snout against the door. Then it turned away and walked in various directions, each time being brought to a standstill by knocking its head full against some obstacle. This condition of total blindness continued only half an hour. After this it began to give evidence of returning vision, at first imperfect, shown by attempting to seize and climb on to a hot pipe before it could reach it. But within two hours vision was acute enough to enable it to pick up a piece of apple lying to its right side; and it was able to run about the laboratory with a companion, avoiding obstacles on either side, passing them quite closely and never running against them. There was no sign of hemiopia.

After further observation for half an hour the animal was adjudged to have fair if not perfect vision with its right eye, and the left was then unclosed, and the animal returned to its cage.

Next day it was in all respects quite well, and no defect, sensory or motor, could be made out.

Three weeks afterwards the *right angular gyrus* was similarly exposed and cauterised. During the surgical dressing the animal was awake, with both eyes open, the pupils large and contractile, and the conjunctival reflex equally distinct in both eyes.

When the animal was allowed free it began almost immediately to run about all over the laboratory, avoiding obstacles, and apparently with vision unimpaired, at least as regards the power of direction of all its movements.

After it had run about thus for a time its *left* eye was then bandaged. On this the animal struggled to get rid of it, and in doing so while it ran knocked its head against obstacles. It made no sign of perception of threatening gestures, and after observation for some time it was adjudged either blind, or to have greatly-impaired vision in the right eye.

Next the right eye was bandaged, the left being freed, whereupon the animal ran away, clearing obstacles everywhere, and running away if threatening gestures were made.

Next day the same experiments were repeated on the right and left eye respectively, but the animal indicated by its movements and its power to pick up articles of food, &c., that it had equally good vision in either eye. No defect, hemiopic or otherwise, could be made out.

The animal continued in perfect health for seven weeks, when the openings in the skull were again exposed, and seen to be covered with membrane, continuous with the dura mater and flush with the rest, there being no hernia cerebri.

The posterior margins were incised, and the anterior margins of both occipital lobes exposed for about $\frac{3}{8}$ ths of an inch behind the cortical lesions previously made. These portions of the occipital lobes were cauterised up to the previous lesions.

During the dressing of the wounds the animal recovered from its narcotic stupor, opening both eyes widely.

The animal was wrapped in a blanket and laid beside the hot-water pipes to recover, but having been left for ten minutes it was found free from its blanket and mounted on a pipe, and on being approached made grimaces, jumped down, and after a run round the laboratory ran into the partially-open door of its own cage, and sprang up on its usual perch. All this happened within a quarter of an hour of the operation.

Not a single symptom could be detected. Its sight seemed unimpaired, hearing acute, other sensory faculties and motor powers unaffected.

The animal continued in good health, and to all appearance normal, until it was

killed with chloroform four months after the last operation, and over six months from the date of the first.

Post-mortem examination.—The brain was everywhere normal, except in the regions where, as above described, the lesions had been made. Over these the dura mater was adherent, but elsewhere it was separable, and there were no indications of diffused inflammation.

In the right hemisphere (Plate 20, fig. 5) the angular gyrus was obliterated except as regards a thin strip of cortical matter bounding the intraparietal sulcus, and at the upper extremity of the arch formed by the two limbs. The lesion extended posteriorly across the line of the parieto-occipital sulcus, undermining the anterior extremity of the occipital lobe. The edge of the uninjured cortex of this lobe was 4–5 mms. from the anterior extremity of the first occipital fissure.

The superior extremities of the first and second temporo-sphenoidal convolutions merged gradually into the lesion.

Horizontal sections through the lesions showed that the cortical matter of the convex aspect of both limbs of the angular gyrus had been completely removed, but that of the sulci separating them from the adjacent convolutions was intact. The grey matter at the bottom of the parieto-occipital sulcus, which is here folded deeply inwards, was also intact. That of the superficial aspect of the margins of this sulcus was destroyed.

In the left hemisphere the amount of destruction of the grey matter was almost exactly the same as in the right; but the limbs of the angular gyrus were more completely obliterated, and the lesion extended somewhat farther back into the convex aspect of the occipital lobe.

The grey matter at the bottom of the sulci was not injured.

Remarks.—This case is interesting both in its surgical aspects, showing how little effect even repeated operations on the brain may have on the well-being of the animal, and also from a physiological standpoint.

There was for a short time after the animal was otherwise in full possession of all its faculties and powers, complete blindness in the eye opposite the injured angular gyrus. This gave way to such restoration of vision within two hours as to enable the animal to direct its actions without any appreciable deficiency. There was no hemiopia either immediately after the lesion or subsequently.

The effects of destruction of the other angular gyrus, which however was less extensive than that of the first, was somewhat unexpected, as being unlike the usual results following injury to the one angular gyrus when the other is intact.

At a time when any affection of the left eye was imperceptible, there was evident impairment of vision of an amblyopic not hemiopic character in the right eye, *i.e.*, the same side as the second lesion.

It would thus seem that the angular gyrus is in relation to both eyes, and that though usually the cross effect is the only pronounced one, yet the direct one may be

more evident when the other angular gyrus has been more extensively destroyed some time previously. (See Experiment 5*.) The absolutely negative character of the subsequent extension of the lesions into the anterior parts of the occipital lobes was also a remarkable fact in this case.

Experiment 5 (Plate 20, fig. 7).*

In this animal the *left angular gyrus* was exposed in the usual manner, and cauterised with the galvanic cautery.

The left eye was secured, and the animal allowed to recover from stupor.

At the end of half an hour it was evidently wide awake but would not move unless touched. At this time it was removed from its cage and placed on the floor, whereupon it began to grope about in a sprawling manner, knocking its head against every obstacle in its path. After some minutes of this behaviour it subsided and refused to move. It made no sign of fear at threatening gestures, and did not wink at a thrust of the finger at its eye, until the finger almost quite touched the conjunctiva, when the usual reflex closure occurred.

Half an hour later the same tests were employed with precisely the same indications of total loss of vision.

At the end of still another half hour, while it was lying quietly in its cage, it was gently laid hold of without noise to attract its attention, whereupon it bounded away with an expression of fear or surprise, and ran full tilt against the leg of a table where it remained groping and sprawling for a few moments. It then again started off, and this time ran against the wall, against which it sprawled helplessly. Similar things were repeated.

It gave no sign of perception when it was cautiously approached without noise, but when a slight noise was made with the lips quite close to it, it darted off and came against the wall as before, where it lay down.

Half an hour later, while it was resting quietly in a corner with its eye open, the light of a lantern was flashed in its eye, but it gave no sign. Creeping up to it cautiously without exciting its attention the observer made a slight whisper close to its face, whereupon it peered eagerly, but evidently remembering the results of running away, it crouched down and would not move.

Half an hour later, when it was quiet in its cage, it started suddenly on being touched and ran its head into a corner, where it crouched.

Next day, its left eye being still closed, it showed unmistakably the possession of vision with the right eye. It laid hold of things as usual, and ran about the laboratory in every direction, passing obstacles to the right and left with perfect precision, and ducking its head to pass underneath bars as it ran along the top of the hot-water pipes of the laboratory.

No defect of vision, amblyopic or hemiopic, could be detected. The animal was in

perfect health and in every respect normal, and continued so for three weeks, when the *right angular gyrus* was similarly exposed and cauterised on the surface, close up to the parieto-occipital fissure.

During the dressing of the wound the eyes were open, pupils equal medium size, and the conjunctival reflex distinct.

The animal was wrapped in a blanket and laid in a warm place.

Within a quarter of an hour it got up, shook off the blanket, and on being touched gave a screech and made off, knocking his head twice, till it was brought up in a corner of the room, where it remained at rest.

Similar results were obtained on repeated tests continued for an hour and a quarter. When urged to move it constantly knocked its head as it ran, or was brought to a dead stand against a wall. It was extremely on the alert, and made grimaces if approached without caution against sound; but it paid no attention to threats, &c., made at a little distance quietly and without noise.

Two hours after the operation the animal began to show signs of returning vision. It shrunk when the light of a lantern was flashed in its eyes at some distance. It was also able when near the hot pipes to climb on to them as usual. Whether it saw very clearly could not be made out, but it was able to guide its movements without vacillation or uncertainty.

Next day the animal was in every respect well, eating heartily, and running about actively, and showing full possession of sight to every test that could be devised.

Six weeks subsequently the lesion of the left hemisphere was extended anteriorly into the *ascending parietal convolution*, the grey matter of which was seared with the cautery superficially.

In a quarter of an hour after the operation the animal got up and walked to the other side of the laboratory where its companions were, and tried to get among them in their cage. It walked lame and stumbled frequently, owing to an evident weakness and tendency to give way of the right arm and hand. It was observed to try and pick up a crust of bread with its right hand, but though it thrust its arm forwards it could not grasp the object. On attempting to climb up the bars of the cage it fell down when it tried to grip with its right hand.

An hour subsequently the animal was very active. It was observed in climbing to trust its weight almost entirely to its left hand and foot. The right hand had not entirely lost the power of closure, but the grip was very weak as compared with the left, and was easily overcome; and frequently the animal dropped what it tried to hold in its right hand.

Two days subsequently the weakness of the right hand was still very evident, and it was also noted that the right foot was not moved so well as the left, being lifted *en masse*, without the dorsal flexion of the foot and spreading of the toes seen on the left side. In climbing, the grip of the right hand and foot was very feeble, the weight being trusted almost entirely to the left, which clung firmly on the bars.

Slight pinching of its fingers and toes on the right excited precisely the same indications of attention and uneasiness as on the left.

Five days after the last observations the same condition was seen. Experiments were made, consisting in suspending the animal by the hand or foot. When this was done with the left hand or foot, the animal speedily got its mouth up conveniently to give a bite, but quite failed to grip and pull its body up to do the same, when suspended by the right. But on one occasion, when held by the right hand, and failing to raise its head to bite, it skilfully laid hold of its right arm with the left, pulled its body up, and so nearly effected its purpose.

Walking was with the same limp as before.

At the end of four months the weakness of grip of the right hand and foot was still distinctly perceptible.

Seven months after the operation the animal seemed somewhat paraplegic. The cause of this was doubtful, but it was probably the result of a heavy tray having fallen on its back some time before.

An examination of the right hand indicated some degree of rigidity of the flexors, and forcible passive extension of the wrist and fingers seemed to cause uneasiness and spasm of the muscles of the upper arm and shoulder.

The animal was found dead one morning by the laboratory attendant, exactly ten months after the first operation.

Post-mortem examination.—The brain was somewhat soft, not having been removed for many hours after death, and was injured slightly during removal and separation of the membranes adherent over the seat of lesion.

On the *right hemisphere* the angular gyrus had its limbs and sulci almost obliterated, but the grey matter at the bottom of the sulci was intact. The surface of the occipital lobe was somewhat ragged and soft for some distance behind the parieto-occipital fissure, the results of post-mortem injury.

The upper extremity of the arch formed by the two limbs of the angular gyrus was still more or less distinct.

On the *left hemisphere* the grey matter of the angular gyrus was also similarly destroyed superficially, as well as the greater portion of the convexity of the ascending parietal convolution, and a considerable portion of the postero-parietal lobule. But the grey matter of the intra-parietal sulcus was intact, as well as that of the parieto-occipital sulcus.

There was also superficial erosion over a considerable portion of the occipital lobe, posterior to the parieto-occipital sulcus, due to post-mortem injury, in removing the brain and separating the adherent membranes.

Remarks.—This case shows the occurrence of total loss of vision, for several hours during which observation was maintained, in the eye opposite extensive destruction of the cortex of the angular gyrus. Next day this had disappeared. On subsequent similar destruction of the other angular gyrus, sight was evidently abolished com-

pletely for two hours in both eyes. But restoration of vision occurred to such an extent after this, that no perceptible deficiency could be detected, so far as could be ascertained by any tests applicable to the lower animals. Whether vision was perfect in such a degree, central and peripheral, as might be ascertained by accurate perimetric tests in a human being, did not admit of determination.

There was no further impairment of vision when the lesion of the left hemisphere was extended forwards into the ascending parietal convolution, but there was a marked deficiency as regards the motor power of the right hand and foot, which continued till the animal's death many months subsequently. The defect did not amount to actual paralysis, but only to paresis, a condition which can be readily accounted for by only partial destruction of the centres concerned in the movements in question. (See further, Section III., p. 510).

In the next experiment on the angular gyrus it was considered advisable at the same time to divide the corpus callosum, or part of it, with a view to determine whether such a lesion would have any influence on the otherwise speedy compensation of unilateral lesion of this gyrus. Previous to this an experiment had been made in order to determine the effects, if any, of division of the corpus callosum alone. The particulars of this experiment are as follows.

Experiment 6 (Plate 20, fig. 8).*

Two trephine openings were made over the anterior and posterior extremities of the corpus callosum, and the two openings joined by an incision with a HEY'S saw close to the middle line. The longitudinal sinus was exposed, and the dura mater divided along the left margin, so as to allow access to the longitudinal fissure. A small aneurism needle, bent at an obtuse angle, was then passed between the hemispheres, and the corpus callosum scratched through, so far as could be judged by *tactus eruditus*. There was some hæmorrhage welling up between the hemispheres, but not to any extent, and ceasing speedily.

The animal was rather weakly before the operation, and remained prostrate for some time. It was not observed for more than an hour, and nothing definite was made out.

Next day it was still rather languid, but it was able to move about, though the right arm and leg were somewhat weak.

Sight was evidently good, and hearing acute. Tactile sensibility was unimpaired, judging from the manner in which it attended to and resented cutaneous irritation. Smell was evidently also retained, as it seemed fond of the smell of bergamot held under its nose.

Except for the weakness of the right arm and leg, the cause of which is explained below, the animal, though feeble, was otherwise in full possession of all its senses and motor powers.

The animal died two days after the operation, apparently from general prostration.

Post-mortem examination.—On examination of the wound there was no sign of repair, the edges being ununited. The hemispheres were slightly glued together in the longitudinal fissure, evidently by hæmorrhagic effusion, and this was particularly in the meshes of the pia mater along the inner aspect of the ascending frontal and parietal convolutions. The cortex here was somewhat softened, evidently caused by the operation.

On separating the hemispheres it was seen that the corpus callosum had been completely divided, from within a quarter of an inch from the anterior extremity or genu, to the posterior extremity or splenium, where only a few transverse fibres over the corpora quadrigemina remained undivided. There was no effusion into the interior of the ventricles, and the brain, except at the region above mentioned, was otherwise perfectly normal.

Remarks.—The weakness of the right arm and leg in this case is readily accounted for by the partial lesion of the cortex of the upper and inner aspects of the ascending convolutions. Otherwise the operation of division of the corpus callosum is seen to be entirely negative as regards sensory or motor powers.

*Experiment 7** (Plate 20, figs. 9, 10, 11).

In this animal the *left angular gyrus* was exposed and cauterised up to the parieto-occipital fissure, and an aneurism needle was inserted between the hemispheres, and the *corpus callosum* torn through to a considerable extent.

The left eye was securely closed, and the animal allowed to recover from its narcotic stupor.

In half an hour it began to move about spontaneously, though rather unsteadily.

An hour and a quarter after the operation it walked about the laboratory, knocking its head against legs of chairs and other obstacles in its path.

When a piece of apple was held under its nose, it grabbed it and ate. It continued to walk about here and there, every now and then coming to a dead halt full tilt against a wall.

Three hours after the operation it again, in running through the laboratory, came full tilt with its snout against a wall, where it rested. While it was resting quietly we crept up to it, but the animal, though with eyes wide open and looking towards us, made no sign of perception. Threatening grimaces likewise were without effect, but on making a noise with our lips the animal seemed alarmed, peered forwards, and yet, though it came quite close to our faces, seemed to see nothing. It was tried to right and left in the same way, but there was no sign of vision to one side or the other.

Next day, the left eye being still closed, the animal ran about in every direction, ducking under bars, passing objects to right and left with the utmost precision, and never once knocking against anything on one side or the other. Not the slightest

impairment of vision could be detected, and it was able to pick up the minutest objects lying about in its cage or thrown down near it.

The animal was a very agile jumper, and would take a flying leap over one's shoulder when an attempt was made to lay hold of it.

Five weeks after the above operation the *right angular gyrus* was exposed and similarly cauterised.

During the dressing of the wound the animal had recovered from its stupor. The eyes were both open, the pupils small, and the conjunctival reaction distinct on both sides.

When freed the animal almost immediately began to run about, knocking its head against various obstacles. This, however, continued only for a few minutes, and within half an hour it was able to stoop under the cross bar of a table which came in its way, and on coming to its cage thrust its hand between the bars. At this time both eyes were left open. The right eye was now securely closed. Vision still continued, however, with the left eye to some extent, but indistinct, as it tried to lay hold of things before they were within reach.

For an hour numerous and careful observations were made as to whether vision was impaired to one side more than the other, but this was clearly not the case, for the animal very speedily showed that it could see to both sides by picking up currants scattered on the floor to either side and with either hand indifferently.

The recovery was most rapid, and an hour after the operation it was not possible to detect any deficiency in the animal's powers of vision, or otherwise.

It continued in every respect perfectly well until its death by chloroform four months after the last operation.

Post-mortem examination.—The surface of the brain was everywhere normal except in the region of the angular gyri, where the membrane, continuous with the dura mater stretching across the orifices in the skull, was adherent. On removal of this it was seen that the left angular gyrus was obliterated, its place being indicated by a depression caused by the destruction of the cortex. At the bottom of the sulci separating the limbs of the angular gyrus from the ascending parietal convolution, the superior temporo-sphenoidal convolution, and occipital lobe, the grey matter was, however, uninjured. The lesion shelved gradually into the anterior boundary of the occipital lobe (fig. 11).

On the right hemisphere the lesion of the angular gyrus was less complete and more superficial. A thin strip of uninjured cortex bounded the intra-parietal sulcus, and the upper extremity of the arch formed by the two limbs of the gyrus was also visible. The convex aspect of the limbs of the angular gyrus had been removed, but the folding of the grey matter in the bounding sulci was still very apparent and uninjured. The convex aspect of the upper extremity of the superior temporo-sphenoidal convolution was also involved in the lesion, a considerable portion of this having been also destroyed. The lesion sloped gradually into the anterior boundary of the occipital lobe (fig. 10).

On separating the hemispheres, which were slightly adherent on their median aspect along the longitudinal fissure, a cicatrix nearly an inch long was seen in the corpus callosum, somewhat nearer the left hemisphere than the right (fig. 9).

The cicatrix was deepest posteriorly, and reached within a few millimetres of the posterior boundary. The exact depth of the original incision which had thus become cicatrised was difficult to determine.

(The photographs were taken by Mr. J. M. THOMSON.)

Remarks.—This case shows that division or injury of the corpus callosum does not appreciably affect the rapidity of compensation of the primary results of lesion of the angular gyrus.

The total blindness of the eye opposite the more extensive destruction of the angular gyrus, viz. the left, was very manifest; but the subsequent less extensive lesion of the other angular gyrus produced only very transient effects, which might have escaped observation unless tested for soon after the operation. But here, as in many other cases, the facts related show that at a period when all other faculties and powers were unimpaired, vision was distinctly defective. The period of reliable observation is not to be determined by the mere length of time that has elapsed since the operation, for the rapidity of recovery is very variable, but by the indications that the animal is on the alert, and otherwise in full possession of its other powers. In this case the second operation seemed to have caused so little general prostration that the animal was able to run about almost immediately as if nothing had happened to it.

*Experiment 8** (Plate 21, figs. 12, 13, 14).

In this case *both angular gyri* were exposed at the same operation and destroyed as completely and accurately as possible by means of the galvanic cautery.

The animal remained apparently sound asleep for nearly two hours. At this time it began to sit up and move about a little in a very cautious and shaky manner. Both eyes were opened widely, the pupils were large and equal, and the conjunctival reflex was very distinct in both eyes.

It turned its head sharply to sounds, but made no sign of perception when a light was thrust or flashed close to its eyes, or when threatened in various ways.

Three hours and a half after the operation when urged to move it knocked its head against every obstacle in its path. Its motor powers were unimpaired, hearing acute, and tactile sensibility evidently fully retained, as it shook off flies when they settled anywhere on its body.

Next day, twenty-four hours after the operation, the eyelids were somewhat oedematous, interfering with the full-opening of the right eye especially. The left was sufficiently open for distinct vision.

The animal was very unwilling to move, and when urged to do so knocked its head against every obstacle, and occasionally sprawled with its hands in the air as if to lay hold of something.

On the following day the œdema of the eyelids had entirely disappeared, and both eyes were freely and widely open. Still reluctant to move. When urged to do so, merely turned round or groped and sprawled about. When a cherry was placed to its lips it bit a piece eagerly and seemed to enjoy it. The cherry was then laid on the floor in front of it, but it was unable to find it though looking eagerly for it. The animal enjoyed its food, which it found by groping about with its hands in its cage.

On the fourth day there were some indications of returning vision. A piece of orange was held before it, whereupon it came forward in a groping manner and tried to lay hold, but missed repeatedly. When the piece of orange was laid on the floor it stretched out its hand over it, short of it, and round about it before it succeeded in securing it.

When urged to move it did so very cautiously, and occasionally came close up to the wall before it stopped, but it did not knock its head as before. It was observed that when it accidentally dropped a piece of food when eating, it could only find it with difficulty, and equally so in front and to either side. Many similar observations were made.

On the fifth day the animal came out of its cage spontaneously and walked about. It never now knocked its head. It was evidently able to see its food, but constantly missed laying hold of it at first, putting its hand beyond it or short of it.

On the sixth day the animal walked about freely, avoiding obstacles, but vision was evidently defective, as on several occasions it was seen as if about to climb before it had come sufficiently near the ledge on which it wished to mount. It was, however, able to pick up grains of rice scattered on the floor, but always with uncertainty as to their exact position.

Watched from day to day the animal continued to manifest the same indications of defective vision.

Four weeks after the operation the animal seemed in a feeble state of health and disinclined for exertion. The same want of precision was still seen as regards its power of putting its hands on objects it wished to pick up. This was apparently equal in all directions.

At this date when it was walking about on a table it tumbled off, having come too near the edge without seeming to be aware of the fact.

After this, being the holiday season, no further observations were made for a time, and the animal died in the interim two months and a half after the operation.

Post-mortem examination.—The brain not being removed immediately was somewhat soft, and suffered some damage in removal.

Examined after hardening in spirit the general aspect was normal, except in the region of the angular gyri.

The left angular gyrus had entirely disappeared with the exception of a small portion of the lower extremity of the anterior limb. The neighbouring convolutions looked as if they had been dissected out (Plate 21, fig. 13).

A horizontal section of the hemisphere at the point of greatest depth of the lesion, viz. : at the upper extremity of the superior temporo-sphenoidal convolution, showed that the lesion involved only the ridges and sulci of the angular gyrus, the stem of medullary fibres passing backwards to the occipital lobe being uninjured. The cortex of the occipital lobe was intact (Plate 21, fig. 14).

In the right hemisphere the angular gyrus was also quite obliterated, except a thin strip of cortex intervening between the ascending parietal convolution and the upper extremity of the superior temporo-sphenoidal convolution, which forms a wedge between the two limbs of the angular gyrus (Plate 21, fig. 12).

The posterior limb of the gyrus which becomes continuous with the middle temporo-sphenoidal convolution retained only some traces of the cortex at the bottom of the sulci separating it from the superior temporo-sphenoidal convolution and the occipital lobe.

The convexity of the occipital lobe was slightly eroded superficially from post-mortem injury.

The medullary fibres of the occipital region were seen in horizontal section to be altogether intact (Plate 21, fig. 14).

Remarks.—In this case the angular gyri had been effectually obliterated on both sides without injury to the occipital lobes or their medullary connexions. The result was total blindness without affection of the other senses or motor powers. The total blindness lasted only three days, but vision continued permanently impaired, and showed no further signs of improvement during the month in which the animal was kept under observation. The condition was one of double amblyopia.

*Experiment 9** (Plate 21, fig. 15).

In this animal the occipital region was exposed on both sides, and *both occipital lobes* were severed with the galvanic cautery, and scooped out bodily. The line of incision in both cases passed between the anterior extremity of the first occipital, and the parieto-occipital sulcus.

The portion removed on the right side weighed 1·9 grammes; that removed on the left weighed 2·1 grammes.

In half an hour after the operation the animal sat up and wanted to move about, but it was kept still, wrapped in a blanket, to prevent risk of hæmorrhage. Both eyes were open equally, the pupils smallish, and the conjunctival reflex equally distinct on both sides.

For two hours, though it was looking about as if it saw, no definite test of vision was made; but at the end of that time it went and sat down beside the next cage and allowed the other Monkeys to handle it, and examine its head. It then, of its own accord, went into its own cage and sat down. A piece of apple was thrown into the cage, and though it fell a full arm's length away, the animal, without the slightest hesitation, or want of precision, put forth its left hand, picked it up, and ate it.

Half an hour later several similar tests were made. A piece of apple was thrown near it. This it took, and began to eat. On the piece being taken from it, it seized another piece lying in the cage and ate this, and having finished it, came forward a few steps and picked up another piece lying on the floor.

There was thus the most complete proof of retention of vision. Hearing was acute; cutaneous sensibility was unimpaired, the slightest touch anywhere on its body exciting its attention. It smelt the apple before eating, and evidently enjoyed the taste.

Next day the animal seemed in the most excellent health. Took things offered it with the utmost precision, and picked articles of food from the floor. It came out of its cage when the door was open, and had a look at its companions, and playfully tickled the ear of a kitten which came past its cage.

From this time onwards it continued in perfect health, and without the slightest discoverable impairment of vision or other deficiency.

Nearly six weeks after the first operation the *left angular gyrus* was exposed, and this and the anterior portion of the remainder of the occipital lobe cauterised with the galvanic cautery. The left eye was securely closed.

Half an hour after the operation the animal was sitting up, on the alert, and listening to the grunts of its companions. When touched it started, and bounced with its head full against the leg of the observer.

An hour after the operation it seemed to have some obscure power of vision, but in running along the top of the hot-water pipes, it knocked its head against the brackets, now on the right and now on the left. Made a vague sort of motion towards a piece of bread held in front of it, but did not reach it.

Constant observation for another hour was made with a view to determine whether it saw to one side or the other better, but without settling the point. It seemed to see better to the left than to the right, and yet on one occasion it turned to the right and took a piece of biscuit with its right hand.

Two hours and a half after the operation it was able to see so well to the left as to be able to pick up grains of oats scattered on the floor towards its left side, and with its left hand. But it took some with the right hand, though not quite precisely, from a heap of grains held in the palm of the hand towards its right.

Next day, twenty-four hours after the operation, constant observation and various tests were made for two hours in respect to the question of vision to the left and right. There was no doubt that though it saw to the left, it also did so to the right. It picked up grains preferably to the left, and with the left hand, but on several occasions it picked up currants, &c., to the right with its right hand. On one occasion it was sitting with the left side close against the wall, but it reached its right hand well to the right side to pick up grains, &c., lying on the floor. Threatened towards the right side it started and ran away. Vision to the right seemed therefore fully established.

Next day similar tests were employed with precisely similar results. The left eye which had been closed, was freed to-day, but no difference was observable in the animal's behaviour or power to pick up things.

From this time onwards the animal seemed in every respect perfectly well. It was very active and vivacious, and constituted itself leader and protector of its companions.

It was killed with chloroform nine months after the first operation.

Post-mortem examination.—The brain was everywhere normal except in the following particulars :—

In the left hemisphere the convex aspect of the limbs of the angular gyrus was superficially eroded, with the exception of a strip of uninjured cortex bounding the intraparietal sulcus. The grey matter in the sulci was uninjured (Plate 21, fig. 15).

The left occipital lobe was represented only by a small angular portion behind the upper extremity of the parieto-occipital fissure.

In the right hemisphere the angular gyrus was intact, but the occipital lobe was represented only by a truncated portion, scarcely one-third of the whole, of a triangular shape, the base directed upwards and the apex downwards, the boundary of the section being at the vertex half an inch behind the parieto-occipital fissure, and thence gradually tapering to one-sixteenth of an inch behind the lower extremity of this sulcus.

Remarks.—This case shows very clearly that notwithstanding the entire removal of at least two-thirds of both occipital lobes, the animal, within two hours of the operation, was able to see and pick up minute objects with perfect precision, recognised and interpreted the meaning of threatening gestures, and acted generally as if it retained its visual faculties in all their integrity.

The additional superficial lesion of the left angular gyrus induced transient total blindness in the right eye, gradually giving place to such restoration of vision that next day it was impossible to detect any visual defect either to the one side or the other.

Though therefore the left occipital lobe was almost entirely removed, and the left angular gyrus extensively injured, and two-thirds of the right occipital lobe destroyed, the animal enjoyed vision so perfect that no defect could be discovered by any tests applicable to lower animals, continued most intelligent and vivacious, and exercised a dominant influence over its companions.

Experiment 1* showed that almost entire removal of one occipital lobe was without appreciable effect on vision; and Experiment 2* showed that considerable bilateral lesions were also negative. This experiment is still more striking.

Reference is also made to "Experiments on the Brain of Monkeys" in the Philosophical Transactions, Vol. 165, Part 2, by Dr. FERRIER. In Experiments XXII. and XXIII. similar facts are related. In Experiment XXIV., in which the occipital lobes (and subsequently also the greater portion of the frontal lobes) had been removed, there was some defect in vision, shown in incorrect appreciation of the distance of objects. In

this case there was considerable hernia cerebri, and the angular gyrus of the right side was involved in the lesion.

As the brain of this animal had been carefully preserved in spirit since 1875, photographs were taken and are here appended (Plate 21, figs. 18 and 19), so that the condition of the brain may be accurately seen.

*Experiment 10** (Plate 21, fig. 17).

In this animal the *left angular gyrus and anterior half of the occipital lobe* were exposed, and thoroughly cauterised, and the *rest of the occipital lobe severed and removed*.

The portion removed weighed 2.55 grammes.

The left eye was securely closed.

The right eye was open, the pupil contractile to light, and the conjunctival reflex distinct.

When the animal began to move about half an hour after the operation it was totally blind, paying no attention to threats, though excessively timid, and knocking its head against obstacles in its path.

An hour after the operation there were some indications of vision, and observations were continued for an hour and a half after this with a view to determine the exact extent, and whether vision was unilateral or not. For a long time it remained doubtful, but it seemed as if vision was abolished towards the right side at least.

Next day blindness towards the right was distinctly proved, as the animal occasionally knocked its head on the right side. The left eye was then unclosed, and the right secured.

Sight seemed improved, but the animal still, especially when hurried, knocked its head on the right side in its career. It was able to pick up things with its left hand towards the left.

On the day following both eyes were allowed free. Defect or abolition of vision towards the right was still very apparent, as on several occasions the animal knocked the right side of its head against the legs of chairs, tables, &c., in its wanderings. To the left it could see, and take hold of things offered it.

On the fourth day after the operation the animal was able to run about, evidently with improved vision, for it did not now knock its head though passing and repassing obstacles on every side. It was observed to pick up grains of oats scattered on the floor, with its left hand.

And at dusk, as it was being pursued into its cage, it knocked its head on the right side, in a dark corner of the laboratory.

On the fifth day it ran about very freely never knocking its head. On this day, in addition to picking up things readily with its left hand, it was seen to turn to the right and pick up a piece of apple, thrown down, with its right hand. On the sixth

it was sitting with its right side close against the left side of another Monkey which was eating an apple. It was looking very eagerly and covetously, and on the apple being accidentally dropped by the other, it reached across with its left hand, seized the apple, and made off with it.

On the tenth day it was seen while sitting on the top of a hot-water pipe to reach down with its right hand, and pick up a chestnut lying in its cage.

On the eleventh day it was seen to spring past objects on either side without once knocking its head.

From the thirteenth day onward it was impossible to discover any traces of hemiopia, as the animal was able to pick up grains of oats, &c., scattered on the floor to the right as well as the left, and without making any perceptible motion of its head.

It seemed to have quite recovered; and it remained in excellent health till it was killed with chloroform five months after the operation.

Post-mortem examination.—The left hemisphere was truncated, exposing the upper surface of the left side of the cerebellum. The convex aspect of the left hemisphere was sharply limited posteriorly by a line corresponding almost exactly with the intraparietal sulcus (the posterior margin of the ascending parietal convolution was slightly grazed). From this line the surface of the left hemisphere sloped downwards and backwards, and ended abruptly at the point where the middle temporo-sphenoidal convolution passes into the occipital lobe.

Of the convex aspect of the occipital lobe scarcely a trace existed. The anterior limb of the angular gyrus, both on its convexity and where it bounds the intraparietal sulcus, had disappeared, and as before stated, the posterior margin of the ascending parietal convolution was also grazed.

The convexity of the posterior limb of angular gyrus was also almost entirely obliterated, but the grey matter in the depth of the parieto-occipital fissure was not destroyed. The upper extremity of the superior temporo-sphenoidal convolution remained clearly defined and intact, except for slight superficial erosion of the cortex. The grey matter of the sulci separating it from the anterior and posterior limb of the angular gyrus was uninjured.

The rest of the brain was in every respect normal. [The vertical line seen in the figure is an accidental defect in the photograph].

Remarks.—In this case we have complete removal of the convexity of the left occipital lobe and the greater portion of the angular gyrus followed by transient total blindness in the right eye, giving place to right hemiopia; and this in turn giving place to such restoration of vision within a fortnight that no defect could be discovered by any methods applicable to the lower animals.

*Experiment 11** (Plate 21, fig. 16).

In this animal the *left angular gyrus and adjacent margin of the ascending parietal convolution* were exposed and the cortex seared with the galvanic cautery.

During the dressing of the wound consciousness was returning; the eyes were open, the pupils moderate size and contractile to light, and the conjunctival reflex equally distinct in both eyes.

The right eye was then bandaged.

The animal having gone to sleep for a quarter of an hour began to move about, indicating vision by making a grimace when threatened; and within an hour after the operation was running about the laboratory, and picking up things lying on the floor, currants, &c.

No defect being ascertainable as regards vision with the left eye, the left eye—that on the side of lesion—was next secured, and the right freed. The animal struggled for some time with the bandage, but not succeeding in getting it off, became quieter. Very shortly, within an hour and a half after the operation, it indicated vision by making a grimace when threatened, and two hours after the operation it was seen to pick up pieces of food from the floor to right and left indifferently.

Some weakness was perceptible in the right hand, which, though used in climbing, occasionally slipped and gave way. There was no defect as regards the sensibility of the hands, and the animal made grimaces and rubbed the palms of both hands when it accidentally placed them on a water pipe which was rather hot.

Next day the animal seemed in perfect health. Sight was to all appearance as good as before. When the right and left hands were tested respectively as to their grip, the right was perceptibly weaker. Otherwise no difference could be observed.

Similar observations were made at intervals with the same results up to four months after the operation, when the animal was again chloroformed and the *right angular gyrus* exposed and *cauterised*, and the *right occipital lobe removed en masse*. The portion removed weighed 2.75 grammes. The animal, as the dressing was finished, was recovering consciousness; both eyes were open, the pupils equal, and the conjunctival reflex distinct in both eyes.

Twenty minutes after the operation a sniff of ammonia caused the animal to wake up and proceed to walk about the laboratory. Hearing was good, as it responded to the grunts and calls of its companions.

It soon gave evidence of vision to the right side, by approaching the laboratory attendant standing on this side, and climbing up his arm.

Two hours subsequently the left eye was bandaged. The animal was able to see and pick up a cherry to the right. To the extreme left front it could not do so, but was able to find a cherry to the left of the middle line, reaching its right hand across the middle line to seize it.

After continuous observation for an hour the left eye was freed, and the right closed. It was evident that the animal lost things to the left of the middle line. It also appeared that vision to the right was limited, for while it seized things to the right of the middle line, yet it seemed to lose things placed to the extreme right.

Next day similar observations were made, with similar results.

On the fourth day the animal was observed for some time with both its eyes free. It was able to pick up grains of corn scattered on the floor, to the right, but not to the left. The right eye was then bandaged. It continued to pick up grains to the right, but not to the left; and in running knocked its head on the left side against the leg of a table.

The left eye was then bandaged, and the right freed. It continued to see well to the right and keenly watched flies buzzing about on this side. It looked about both to right and left, and in picking up grains frequently reached well across the middle line towards the left side. Vision to the extreme left however was deficient.

Similar observations were made on the seventh day.

On the tenth day, when the left eye was bandaged, the animal was able with only a slight turn of the head to pick up grains, &c., towards the left side.

With the right eye bandaged, vision to the right was clear, but things to the left of the middle line were lost.

On the fourteenth day, with the left eye bandaged, the animal ran about, skilfully catching flies with the right hand to the right side, and also to the left with a slight turn of the head. It was also seen on this day to take a fly offered it on the left side, with its left hand; appearing a little uncertain as to its exact position. Did not knock its head anywhere though passing and re-passing objects on the right and left constantly.

On another occasion it was held up facing a wall on which many flies were settled. It caught one or two on its left front with its left hand, without turning its head.

On the seventeenth day it was seen to run about everywhere without once knocking its head, passing close to obstacles right and left. It was also seen to catch flies with either hand to right and left.

The right eye was then bandaged. It still continued able to catch flies with the left hand. Whether vision was equally distinct to left as right could not be determined, but it was certainly not blind to the left side as it had been formerly. Four months subsequently, vision to the right and left was to all appearance equally good, as the animal was able to pick up minute objects to right and left indifferently, and without any abnormal turning of the head. It was killed with chloroform nearly five months after the second operation.

Post-mortem examination.—On the *left side* the grey matter of the convexity of the angular gyrus was merely eroded, and the grey matter at the bottom of the sulci was uninjured. There was also slight erosion of the ascending parietal convolution, and of the upper extremity of the superior temporo-sphenoidal convolution. The occipital lobe was intact, as also the rest of the hemisphere (Plate 21, fig. 16).

On the *right side* the occipital lobe was entirely gone, having been cut off exactly at the parieto-occipital fissure. The ridges of the angular gyrus were also almost entirely obliterated, but the grey matter in the depth of the sulci separating it from the ascending parietal and superior temporo-sphenoidal convolutions was intact. The



upper extremity of the superior temporo-sphenoidal convolution was eroded superficially.

The rest of the brain was perfectly normal.

Remarks.—In this case of superficial destruction of the cortex of the left angular gyrus and ascending parietal convolution there was no perceptible affection of vision on the side of lesion, and none could be made out on the opposite side within two hours after the operation. The right hand was somewhat weaker than the left, but there was no paralysis of any movement.

The subsequent entire removal of the right occipital lobe and considerable destruction of the right angular gyrus caused defect in vision in both eyes which proved to be of the nature of hemiopia to the left. By repeated tests applied to the right and left eye respectively, it was found that the limitation of vision towards the left was greater in the left eye than in the right.

The hemiopic defect gradually diminished, and within three weeks after the second operation it was not possible to discover in the animal's behaviour or mode of activity any such defect as had been at first so evident.

*Experiment 12** (Plate 21, figs. 20, 21, and 22).

In this animal *both angular gyri were seared* by the galvanic cautery, and *both occipital lobes severed and scooped out*. The portion removed from the right side weighed 2.25 grms., that from the left weighed 2.5 grms. On recovery of consciousness the animal was observed to have both eyes open, the pupils of moderate size, and the conjunctival reflex distinct on both sides. This was seen within a quarter of an hour after the operation was finished.

An hour after the operation the animal was able to walk about, moving all its limbs perfectly. Tactile sensibility was unimpaired, judging by its attention to and dislike of being touched on any part. That it could smell was indicated by a sudden grab at a piece of apple placed under its nose, which however it failed to seize.

It was absolutely blind and knocked its head against everything in its path. The slightest sound made in its vicinity caused it to start and look round.

Next day it was well and vigorous. Muscular powers were unimpaired, and every faculty of sense except vision. In this respect it was totally deficient, making no sign of perception of anything in the way of threats, &c., and yet so shy and timid that the slightest touch caused it to start and endeavour to escape. In such attempts it knocked its head full against whatever lay in its path.

Next day the condition was the same. The animal took its food when this was put in its hands, but could not find anything that was merely offered to it, or that accidentally dropped from its grasp.

A week subsequently it was still in the same condition; well in health, and in no wise deficient except as regards vision. An ophthalmoscopic examination of the eyes showed the media, retina, and optic discs of perfectly normal appearance.

The animal soon learnt to find its way about its cage, finding its food by groping. On hearing the sound of food dropped into its cage it would descend from its perch and grope about. Occasionally it would return after an unsuccessful search, though the food lay before its eyes. Accidentally lighting on something with its hands it would take it up, smell, and if not good to eat would throw it down. Satisfied by smell it would eat and exhibit satisfaction by gestures and grunts. Hearing was most keen. It started at the slightest sound, and frequently returned the grunts and calls of its companions. For some weeks it was disinclined to move except about its cage, and generally sat still, except when groping for food. If taken out and urged to move it ran its head against every obstacle in its path. At the end of three months it was less disinclined to move about, and would spontaneously walk out of its cage with a companion Monkey placed with it in the same cage. Many and varied observations and tests were made as to the animal's power of vision, and frequently doubts were entertained as to whether some of its actions were compatible with absolute blindness.

Six months after the operation the animal was able to move about the laboratory and vicinity of its cage with considerable freedom. It had a slouching gait and a somnambulistic-like air, its eyes looking steadfastly in the distance. It seemed to be aware of its proximity to obstacles, and when left to its own cautious mode of progression did not knock against them. It was able to find its way to its companion at some distance, first listening attentively to the noise of its footsteps. It also seemed aware of one's proximity when within close range. It was difficult to approach without exciting the animal's attention. Yet if this were done with the utmost caution against sound it might be approached and the hand waved, or threats, &c., made, without causing winking, or the slightest sign of perception. A nearer approximation of the hand, however, made the animal uneasy and as if aware of the fact. It moved its head and eyes and put out its hand if a stick were waved round and round close to its face, but not if at a sufficient distance to avoid causing agitation of the air in its immediate proximity. Though it still found its food by groping, it seemed occasionally to put its hand out as if it saw. Yet it was unable to find a piece of food which it was allowed first to smell, and which was then laid down in front of it; and it frequently failed to find what it had accidentally dropped.

If, moreover, instead of being allowed to walk about quietly at its own leisure, it was suddenly startled, by sounds or attempts to lay hold of it, it would look terrified and run full tilt against whatever lay in its path.

The condition remained unaltered as time went on.

At the end of nine months its eyes were again carefully examined. The pupils were large, and did not contract to light. The optic discs were seen to be remarkably pale.

The animal died without any evident assignable cause during the winter season, nearly eleven months after the operation. Examination a few days before death

revealed the same absence of flinching or other sign of perception when a light was flashed in its eyes, and the same fixity of the pupils as before noted.

Post-mortem examination.—The aspect of the brain was everywhere normal except in the occipito-angular region of both sides over which the membrane, continuous with the dura mater, was adherent. On removal of this it was seen that on the left side, the occipital lobe had been severed and removed in a line corresponding with the internal parieto-occipital fissure, and the angular gyrus was obliterated both on its convexity and in the sulci, so that the neighbouring convolutions, the ascending parietal with the postero-parietal lobule, and the upper extremity of the superior temporo-sphenoidal, appeared as if dissected out and laid bare (fig. 22).

On the right side the lesion was exactly symmetrical with that of the left, the occipital lobe being removed, and the angular gyrus entirely obliterated (fig. 21).

The corpora quadrigemina and optic tracts looked smaller than usual, but beyond this had no abnormal appearance. The abdominal and thoracic viscera were healthy, but there was some emaciation and absence of fat in the omentum. No local disease could be discovered accounting for death.

Remarks.—This case shows that the complete removal of the occipital lobes and angular gyri on both sides causes complete and permanent loss of vision, followed by atrophy of the optic discs and fixity of the pupils. Apart from blindness there was no defect either as regards motor powers or other faculties of sense. The whole aspect and behaviour of the animal resembled that of one blind, the loss of one sense being compensated for by the acuteness and education of the others.

General Results.

These experiments show that lesions of the occipito-angular region cause affections of vision, without affection of the other sensory faculties or motor powers.

The only lesion which causes complete and permanent blindness is total destruction of the occipital lobes and angular gyri on both sides.

If the lesion extend in front of this region into the ascending parietal convolution some affection of motion is seen in the upper extremity on the side opposite the lesion.

Complete destruction of the angular gyri on both sides causes for a time total blindness, succeeded by lasting visual impairment in both eyes.

Destruction of the convex aspect of the angular gyrus on one side causes temporary abolition or impairment of vision in the opposite eye. The defect is not of a hemiopic character. Subsequent similar lesion of the other angular gyrus causes bilateral visual defect, also only of transient duration. The rapidity of restoration of vision does not depend on the integrity of the corpus callosum.

Deep incisions may be made in both occipital lobes, or the greater portion of one, or both occipital lobes at the same time, may be removed without causing any appreciable defect of vision.

After removal of the greater portion of both occipital lobes lesion of one angular

gyrus causes only the same temporary loss or impairment of vision as occurs from lesion of the angular gyrus alone.

Complete removal of the occipital lobe and greater portion of the angular gyrus on one side causes temporary blindness in the opposite eye, followed by bilateral hemiopia towards the side opposite the lesion. This ceases to be perceptible a few weeks after the operation. Recovery ensues even if the other angular gyrus is also considerably injured.

It appears, therefore, that vision is possible with both eyes when only portions of the visual centres remain on both sides.

SECTION II.

LESIONS OF THE TEMPORO-SPHENOIDAL CONVOLUTIONS.

*Experiment 13** (Plate 22, figs. 23-38).

In this animal the *superior temporo-sphenoidal convolution* was exposed in both hemispheres, and both were destroyed by means of the actual cautery directed along their course with the aid of a director.

The animal had recovered consciousness by the time the dressings, &c., were completed. The eyes were open, the pupils equal and contractile, and the conjunctival reflex distinct on both sides.

Within half an hour after the operation it began to look about, and approaching the bars of the cage, laid hold and climbed up hand-over-hand. When its hands or feet were touched with the point of a pencil it withdrew them, evidently conscious of the impressions.

Two hours after the operation the animal seemed perfectly well, climbing about actively. It tried to lay hold of the pencil with which its hands or feet were touched, with a view of testing its cutaneous sensibility.

It, however, paid not the slightest attention to or gave any indications of hearing the loudest sounds of various kinds made in its vicinity—sounds which invariably startled the other Monkeys near it.

Next day there was some œdema of the eyelids, but the animal evidently enjoyed perfect vision. It gave also clear evidence of perception of a touch anywhere on its body. Oil of bergamot held under its nostrils caused it to sniff and make movements of its lips, as if it smelt and liked it. Acetic acid caused it to withdraw its head, and snort or sneeze out. Salt placed on its lips caused it to make tasting movements.

As before, not the slightest sign of perception could be caused by any sounds made in its vicinity.

On the fourth day the various tests were repeated. In every respect the animal was perfectly normal except as regards hearing. No sign of hearing could be elicited. It was noted that while the other Monkeys eagerly listened to the footsteps of any

one approaching, this animal made no sign of curiosity until the person came within the range of vision.

It was noted two days subsequently that the ears did not twitch when loud sounds were made, as they did in the other Monkeys whose hearing was undoubted.

Daily observation was continued, and every variety of test that could be thought of was made with a view to elicit any signs of hearing, but in vain. Occasionally a doubt was raised, but repetition of the tests, and elimination of mere coincidences as regards the movements of the head, failed to establish any satisfactory evidence of hearing.

A month after the operation it was placed in a cage with another Monkey, affected with hemiplegia. While sounds made in the vicinity invariably excited the attention of the hemiplegic animal, the other would go on quietly with what it was engaged in, without appearing to have noticed anything.

The animal was exhibited, six weeks after the operation, before a specially invited number of the physiologists attending the International Medical Congress in London in August, 1881. While it was climbing about before the audience a percussion cap was suddenly exploded in its neighbourhood without causing the slightest start or sign of perception;—in marked contrast to the behaviour of its hemiplegic companion exhibited at the same time. (See the Transactions of the International Medical Congress, 1881, vol. i., p. 237.)

Six months after the operation the animal was in the same condition, in excellent health and spirits, and deficient in nothing but hearing. Sounds which always attracted the attention of the Monkeys failed to elicit any signs of perception. When the experiment was tried of one person going to a distance out of sight, while another watched, and the one in the distance called the Monkeys as if coming with food, &c., all the others would go to the bars of the cage and watch eagerly, while this animal would go on with its occupation quite unheedingly.

Thirteen months after the operation the condition was unchanged. The animal was perfectly well, in full possession of all its other faculties, but manifestly totally deaf.

It was killed with chloroform.

Post-mortem examination.—The orifices in the skull were covered by membrane which was adherent to the brain at these points, but there were no adhesions or abnormalities at any other part.

The left hemisphere.—The membrane was adherent over the lower extremity of the anterior limb of the angular gyrus, and over the region corresponding with the position of the superior temporo-sphenoidal convolution. This had entirely disappeared, its place being indicated by a groove, which was deepest at the lower extremity. A small portion of undestroyed cortex was seen at the lower extremity, separating the groove from the commencement of the fissure of SYLVIVS. Elsewhere there was no trace of the superior temporo-sphenoidal convolution (Plate 22, fig. 24).

Horizontal sections were made of the hardened brain, of which a series of sun-prints are seen in Plate 22, figs. 32-38, arranged from above downwards.

These show that the lesion was strictly confined to the cortex and medullary connexions of the superior temporo-sphenoidal convolution.

Fig. 32, on a level with the island of REIL, shows no trace of the superior temporo-sphenoidal convolution. Fig. 33 shows a minute remnant of the medullary fibres and cortex. Fig. 34, at the upper extremity of the triangular portion of cortex adherent behind the fissure of SYLVIVS, shows that the medullary fibres have been completely severed. Figs. 35 and 36, on a level with the anterior commissure, show similar appearances; while figs. 37 and 38, at the lower extremity of the temporo-sphenoidal lobe, where the lesion was deepest, show that it did not penetrate beyond the medullary fibres of the superior temporo-sphenoidal convolution.

The right hemisphere.—The membranes were adherent over the lower extremity of the posterior limb of the angular gyrus and adjacent margin of the occipital lobe, and over the region corresponding to the upper half of the superior temporo-sphenoidal convolution. The cortex was entirely destroyed, and the medullary fibres severed here, leaving a groove. At the lower half of the superior temporo-sphenoidal convolution the cautery burrowed beneath the cortex without destroying it superficially, but undermining it and causing considerable reduction in superficial extent as compared with the normal. A series of sun-prints of horizontal sections is given in figs. 25-31.

Fig. 25, through the upper portion of the lesion, shows the temporo-sphenoidal convolution destroyed with the exception of a narrow strip immediately posterior to the fissure of SYLVIVS. Fig. 26, at a lower level, shows the medullary fibres completely severed. Figs. 27, 28, and 29 present similar appearances, showing the sinus made by the cautery, hollowing out and almost completely severing the medullary fibres of the superior temporo-sphenoidal convolution; while in figs. 30 and 31 the sinus only undermined the posterior half of this convolution.

Remarks.—This case shows that bilateral destruction of the superior temporo-sphenoidal convolution causes loss of hearing without any other defect either in the domain of motion or sensation. The fact of deafness in this animal was admittedly established before the Physiological section of the International Medical Congress in 1881.

The position of the lesion is proved by the photographs and sections to be in the cortex and medullary fibres of the superior temporo-sphenoidal convolutions, where it was stated to be. On the left side the destruction was most complete; on the right the destruction was not quite complete at the lower half. But the destruction was sufficient to cause such loss of hearing that no evidence could be obtained free from doubt that this continued even in a slight degree.

Experiment 14.*

In this animal the *middle temporo-sphenoidal convolution* was exposed in its upper half on both sides, and both were similarly operated on. With the aid of a director slipped between the dura mater and the cortex, a wire cautery was passed along the course of each convolution with the view of destroying it and its medullary connexions. This could only be done approximately, and as a matter of fact, as will be seen from the post-mortem account, the curve of the cortex was not exactly followed.

After the dressing of the wound the animal was awake, the eyes were open, the pupils equal and contractile, and the conjunctival reflex distinct in both eyes.

Half an hour after the operation the animal when called to opened its eyes and looked up. When it was sitting quietly afterwards with its head between its knees, a splashing of water was made, whereupon it looked up and came to the bars of the cage looking for some.

As regards hearing therefore there was already satisfactory proof. Tactile sensibility was also apparently unimpaired, as it withdrew its hands or feet, when these were touched in such a way as to be entirely out of the animal's range of vision.

Two hours subsequent to the operation the animal was running about. Hearing was acute, the animal frequently stood listening to the Monkeys in the neighbouring cage. Sight was perfect, and tactile sensibility unimpaired.

Next day the animal seemed in every respect normal. Some experiments were made in reference to taste. This was evidently not abolished, as gooseberries on which some aloes had been sprinkled did not seem to be relished.

Four days later further experiments on this point were made, and comparison was instituted between this animal and that of Experiment 13, which was for the time its companion. No. 13* would not eat pieces of orange sprinkled with colocynth, but No. 14*, though evidently disliking the bitter taste, eat several pieces.

The explosion of a percussion cap while the two were engaged with their food caused No. 14* to start while No. 13* paid no attention.

That the animal continued to see, hear, feel, and taste was verified by repeated tests during a fortnight's daily observation subsequent to the operation.

Owing to some oedema of the cheeks, as if from too great tightness of the dressings, the bandages were cut. Next day the dressings were found entirely pulled off, and a small slough of the scalp was found to exist, but the edges of the incisions were healthy. No further observations were made of the animal, it being to all appearance quite well, but it died three weeks after the operation, the slough of the scalp not having healed.

Post-mortem examination.—The openings in the skull situated on each side below the parietal eminence were covered over by recent membrane, and there was no hernia cerebri, and there was no effusion. But on removal of the brain it was found that

there was slight oozing of purulent fluid from the orifice of the wound in the right hemisphere.

The brain was not photographed, but a drawing was made by Mr. F. LE MAISTRE of the right hemisphere, the lesion on the left being similar, though not quite symmetrical. The figures have not been reproduced. In the right hemisphere there was an area of destruction, caused by the cautery, which had entered instead of grazing along the cortex of the middle temporo-sphenoidal convolution. The entrance wound was of the size of a threepenny bit, and was situated in the annectent gyrus between the posterior limb of the angular gyrus and the occipital lobe. This opening was continuous with a sinus, from which the purulent fluid oozed, the direction of which was downwards and forwards beneath the cortex, indicated by the point of emergence, a small orifice a few millimetres in diameter, situated exactly at the lower extremity of the second temporo-sphenoidal sulcus.

The track of the sinus would be accurately represented by the middle and adjacent margin of the third temporo-sphenoidal convolutions.

Frontal sections of the right hemisphere showed the existence of a cavity, which was evidently an enlargement of the original track of the cautery due to the formation of pus. This destroyed the greater portion of the medullary fibres proceeding to the middle and inferior temporo-sphenoidal convolutions. The superior temporo-sphenoidal convolution was intact throughout both in its cortex and medullary fibres.

In the left hemisphere an area of destruction, corresponding with the entrance of the cautery, occupied precisely the same position as in the right hemisphere.

This led into a sinus, the track of the cautery, which pursued a course beneath the cortex, downwards and somewhat further backwards than in the right hemisphere, emerging at the lower extremity of the third temporo-sphenoidal convolution, just external to the uncus, or end of the gyrus hippocampi.

Frontal sections of this hemisphere showed destruction of the medullary fibres proceeding to the middle and inferior temporo-sphenoidal convolutions; while as in the right hemisphere, the cortex and medullary fibres of the superior convolution were intact.

The brain elsewhere was in all respects normal.

Remarks.—The lesions in this case, especially in the right hemisphere, were evidently larger than those primarily made by the cautery, owing to the occurrence of secondary softening. But as no observations were made of the animal for a week before its death, the effects, if any, of the further extension of the primary lesion were not determined.

But the track of the cautery was such as to cause extensive destruction of the medullary fibres of the middle and inferior temporo-sphenoidal convolutions, and yet no defect could be discovered either as regards hearing, vision, tactile sensibility or motor power.

General Results.

These two experiments show that the auditory centre is situated in the superior temporo-sphenoidal convolution. For whereas hearing was totally abolished by destructive lesion confined to this convolution in both hemispheres, there was no impairment of hearing when the medullary fibres of the other convolutions of the temporo-sphenoidal lobe were broken up.

SECTION III.

LESIONS OF THE CONVOLUTIONS BOUNDING THE FISSURE OF ROLANDO (ROLANDIC ZONE).

*Experiment 15** (Plate 23, fig. 39).

In this animal the skull was trephined over the region of the middle of the *ascending parietal convolution of the right hemisphere*. The application of faradic electrical stimulation to this part of the cortex excited movements of the left hand and arm. The part to which the electrodes had been applied was then cauterised with the galvanic cautery.

Three quarters of an hour after the operation the animal in attempting to walk or run fell over on the left side from obvious weakness of the left arm. This tendency to fall over on the left was frequently observed. An hour and a half after the operation it was able to run on three legs, the left arm not being used.

Next day the animal when resting kept the left hand hanging by the side. It took hold of things offered it only with the right hand. In walking it was able to advance the left arm, but limped, as if unable to bear weight on the hand. In climbing it used both legs and the right hand only. Beyond the loss of power in the left hand there was no other defect. The sensibility of the left hand was unimpaired, as the animal's attention was excited by a touch on it, and a slight pinch caused it to exhibit uneasiness and desire to get away.

On the fourth day the condition was the same. The animal advanced the left arm like the other limbs in walking, but seemed unable to bear weight on the hand, and did not use the left hand in climbing. Sensibility to heat on both hands was evidently equally acute.

A fortnight after the operation the animal continued in all other respects well and strong, but limped with the left hand. A large piece of pear being offered to it, it laid hold of it only with the right hand, but finding it too large to hold conveniently in one hand, it did not use the left also, as other Monkeys would, but kept it steady while eating by making a *point d'appui* of the floor. It was observed some time after endeavouring to get a piece of bread out of the cage between the bars. As the piece was rather large and not easily extracted, the animal managed to put its left hand also through the bars, but was unable to grip the object.

A few days subsequently it was seen climbing up the bars of the cage in a peculiar manner. It did not climb hand over hand like Monkeys generally, but proceeded staccado fashion, clinging with the feet, and springing and laying hold higher up with the right hand only.

A month subsequent to the operation the condition was essentially the same. It was observed on one occasion after it had climbed in its peculiar manner to the top of the cage, to put out the left hand for support, but venturing to lean its weight on it, it fell to the ground.

Seven weeks after the operation the animal was taken out and held while the relative strength of the hands was tested. The grip of the right hand was strong and vigorous when one's fingers were placed in it, but on the left side there was scarcely any perceptible pressure. The slightest pinch caused desire on the part of the animal to have the hand released, but the power exerted was very feeble, both as regards the hand and flexion of the forearm.

The animal was found dead one morning two months after the operation, evidently from the effects of cold. The season was the middle of winter and the cold intense. The heating arrangements of the hutches had also failed to keep the temperature up to the usual standard.

Post-mortem examination.—The brain was everywhere normal, except in the region of the middle of the ascending parietal convolution in the right hemisphere. Here the cortex was destroyed, and the medullary fibres exposed, over a somewhat irregular area about the size of a threepenny bit. The erosion trenched anteriorly on the fissure of ROLANDO, while posteriorly there was an elongated superficial erosion of the cortex of the anterior limb of the angular gyrus.

The upper margin of the lesion was abrupt (fig. 39).

Remarks.—The effect of this limited lesion of the middle third of the ascending parietal, and adjoining margin of the ascending frontal convolution, was weakness, not amounting to absolute paralysis, of the left hand, and to a less extent of the power of flexion of the forearm. The sensibility was unimpaired. There was no other defect. Though there was some erosion of the anterior limb of the angular gyrus also, this had nothing to do with the motor defect, as is sufficiently plain from the experiments related in Section 1, where it has been shown that no motor paralysis occurs from complete destruction of this gyrus. Some experiments were also related in this section, showing that weakness of the opposite hand occurred when the lesions extended across the intraparietal sulcus into the ascending parietal convolution.

*Experiment 16** (Plate 23, figs. 40-44).

In this case the left hemisphere was trephined over *the upper extremity of the fissure of Rolando*, and the cortex destroyed at this point with the galvanic cautery.

An hour after the operation the animal was able to walk, but in a lame manner, dragging the right leg.

It was able to climb and in climbing held on by both hands and with the left foot ; but the right leg, except for feeble flexion of the thigh on the pelvis, was not moved.

The face was normal on both sides. Equal signs of sensation were caused by the application of heat to either leg.

At the end of a week the right leg was still dragged in walking, but the thigh could be flexed on the pelvis. The right arm at this time was occasionally subject to spasms, about the shoulder muscles particularly. In the intervals it could take hold of pieces of food, and hold them while eating.

At the end of ten days the animal, in running, carried the right leg, using the arms and left leg freely. The right arm occasionally exhibited spasm on being advanced in walking or in laying hold of things. This spasmodic tendency entirely disappeared after two days longer, but the right leg was still carried in running, flexed at the thigh and knee.

Three weeks subsequent to the operation the condition was similar, the right leg being capable of flexion at the pelvis and knee, but the foot unable to be used for laying hold or climbing. Some slight movement of the ankle-joint was all that the foot seemed capable of.

A month after the operation the animal was able to run about with great activity, carrying the right leg, and also to make considerable leaps, alighting on its hands and left leg.

Six weeks after the operation the relative strength of the limbs was tested while the animal was held. The hands seemed equal in their grip and power of resisting passive movements. The right leg resisted extension of the thigh and extension of the leg, but the foot could be flexed, extended, and moved in various directions without resistance.

The sensibility to pricking was evidently equal on both feet, judging from the appearance of attention and general movements, but the cutaneous plantar reflex reaction was less distinct on the right than left.

Six months after the operation examination of the patellar tendon reactions showed that the right was considerably exaggerated as compared with the left. There was well marked rigidity. On dorsal flexion of the right foot, the leg bent on the thigh, the hamstring and sural muscles being very tense. When the leg was straightened, which caused evident uneasiness, the foot pointed and could not be dorsally flexed.

Seven months subsequent to the operation the same condition of rigidity of the right leg was very marked. The cutaneous plantar reflex of the right foot was also distinctly less than of the left.

Eight months after the operation the rigidity was still more pronounced, extension of the leg causing pointing of the toes, dorsal flexion of the foot causing flexion of the knee, and abduction of the thigh causing tension of the adductor muscles. All these passive movements caused uneasiness when the antagonist muscles were put on the strain.

The animal, otherwise perfectly well, was killed with chloroform at the end of this period—eight months after the operation.

Post-mortem examination.—The brain was everywhere normal except in the region of the upper extremity of the fissure of ROLANDO in the left hemisphere. Here the membrane which covered the orifice in the skull was adherent. On this being separated, a destructive lesion of the cortex was found, consisting of a cavity or hollow depression caused by loss of substance, situated at the upper extremity of the ascending parietal and frontal convolutions, running across the upper end of the fissure of ROLANDO, parallel to the longitudinal fissure. The cavity commenced 1 centim. anterior to the parieto-occipital fissure, and extended forwards for 1.5 centim. Anteriorly it tapered and passed into a superficial erosion, caused by adhesion and separation of the dura mater there, which occupied an irregular area over the upper extremity of the ascending frontal, and base of the first frontal, convolutions.

These appearances are seen in the accompanying photograph, which is somewhat larger than the natural brain (fig. 40).

Frontal sections through the lesion showed that it was purely superficial, the cortex being merely sheared away from the subjacent medullary fibres.

The medullary fibres proceeding from this point to the internal capsule were the seat of degeneration, and stained less readily with carmine than the rest of the medullary fibres. This is seen in the accompanying sun-print of one of these sections (fig. 41).

Microscopical investigation of the spinal cord after hardening in bichromate of ammonia, demonstrated the existence of an area of sclerosis in the pyramidal or postero-lateral tract of the right side of the spinal cord through the cervical, dorsal, and down to the lumbar region.

Figs. 42-44 are microphotographs, enlargements of about 12 diameters, of a section of the cervical (fig. 42), dorsal (fig. 43), and lumbar region (fig. 44) of the cord respectively. The sections were somewhat imperfect owing to the cord being rather brittle from too long maceration in the bichromate solution, but they show very clearly the dark area of sclerosis external to the posterior horn in the cervical region; the same in the dorsal region approaching nearer the surface, and somewhat less distinctly, owing to less perfect section and photograph, immediately external to the posterior horn of the lumbar region, coming quite superficial at this point. [Figs. 43 and 44 have been printed too dark.]

Remarks.—This case shows very clearly that a lesion of the cortex in the region where electrical irritation causes movements of the opposite leg, gives rise to a permanent monoplegia of this limb; the affection being one purely of motor power without loss of sensation. The lesion did not involve the whole of the cortical region, irritation of which causes movements of the opposite leg, nor was the paralysis of the leg absolute, nor did it affect all movements equally. Those most affected were the movements of the foot. The case further demonstrates the important fact that a purely cortical lesion is followed by descending degeneration through the whole

length of the pyramidal tract which connects the region of the cortex with the spinal region whence the motor roots of the limb emerge.

It was noted that for several days subsequent to the operation a spasmodic tendency was observable in the right arm, especially as regards the shoulder movements and when the animal extended the right arm forwards.

This receives a satisfactory explanation in the inflammatory adhesion of the membranes and superficial erosion of the cortex in the region of the upper extremity of the ascending frontal convolution and base of the first frontal. The region specially implicated was centre 5 (FERRIER), electrical irritation of which causes extension forwards of the arm.

The adhesion was probably caused by the use of styptics to still hæmorrhage, which occurred to a considerable extent during the operative procedure.

But as the irritation subsided the right arm ceased to be affected by spasm, and no permanent abnormality was created.

*Experiment 17** (Plates 23 and 24, figs. 45-51).

In this animal, a large Monkey of the Cynocephalic type, the right hemisphere was exposed over the *upper half of the ascending frontal and ascending parietal convolutions*, and this region was destroyed by the galvanic cautery, as close up to the longitudinal fissure as could be reached without exposing this to view.

It was observed that as the animal was regaining consciousness during the dressing of the wound, it used not only the right arm and leg, but also made some flexion and extension movements of the left thigh; the left arm was not moved.

Half an hour after the operation it was found that pricking the sole of the right foot caused the animal to struggle and withdraw the foot, whereas pricking the left foot caused the animal to struggle and express uneasiness, but the foot was not moved.

A similar observation was made as regards the right and left hand. The animal evidently from its gestures felt the stimulus as well on the left as right, but it could not withdraw the left hand.

Next day the animal seemed in capital health, but was hemiplegic on the left side.

The face was not affected. In grinning the two sides of the face acted equally. The animal was able to flex and extend the left thigh feebly, and also extend the left leg, so that it could raise itself when it wished to take a piece of apple offered it at some height above the head. This it took with the right hand. The left arm was kept at the side in a state of semiflexion. It was observed in struggling to make also some flexion of the fingers of the left hand. Heat applied to either hand or foot excited the same grimaces indicative of sensation.

On the fourth day the condition was similar. In walking the left arm was kept in the semiflexed position and the left leg was dragged, the toes catching on a ledge which the animal was crossing.

Three weeks after the operation the weakness of the left side was still very evident. There was feeble power of extension and flexion of the left thigh and extension of the left leg; the left foot was dragged in walking; the left arm was generally kept by the side in a semiflexed position, but some flexion of the forearm and flexion of the fingers was occasionally observed in struggling.

A few days subsequently it was seen, when struggling to lay hold of a piece of apple with its right hand and not able to reach it, to put forth its left hand feebly and close its fingers over it.

At this period the animal was held while the resistance to passive movements of the limbs respectively was tested. There was very feeble power of resistance to passive movements of the left leg, while this was very vigorous in the right. There was in the left arm special resistance to the passive extension of the forearm.

A month after the operation the animal was able to move about actively and climb. In climbing the left hand was used feebly to grip the bars of the cage, but no weight was rested on it. The left foot was dragged in walking, and no grip was made with it in attempts at climbing.

The left patellar reaction was greater than the right. The cremasteric reflex was more distinct on the right than left side. The cutaneous sensibility was to all appearance equally acute on both sides; pinching, heat, &c., eliciting equal attention and signs of uneasiness.

Two months after the operation the weakness of the left arm was still very evident. The animal could use it feebly both in climbing and for prehension. The left leg was especially weak. In attempts at climbing the left leg was only feebly flexed and never raised so high as the other, while the grip of the toes was almost nil. In jumping down the animal always alighted only on the right foot.

Ten days after the last observation a lesion was established in the left hippocampal region, the effects of which will be described subsequently (Section 5, Experiment 24*). Continuing the history of the condition of the left side, it was found, on examination eight months after the operation, that while the animal was struggling against being held, the left leg was little or not at all used. Vigorous gripping was made with the right. There was evident rigidity of the left leg. The foot was kept more or less pointed, and dorsal flexion caused great tension of the sural muscles. The left hand was very feeble as compared with the right, and there was considerable resistance to passive extension of the forearm,—the biceps and other flexors of the forearm becoming tense.

The left patellar reaction was exaggerated. The left superficial reflexes were generally less distinct than the right.

The animal resented pinching, pricking, &c., on the left side as much as on the right.

Fifteen months after the operation the condition was similar. It was observed at this time that frequently when the animal was resting its weight on the left foot, clonus came on, causing the leg to dance.

Nineteen months after the operation, just before the animal was killed with chloroform, an examination was again made as to the relative strength of the limbs while the animal was held on its back.

It struggled violently with the right leg, gripping very tightly with the right foot whatever it could lay hold of, but the left leg was scarcely used at all, and no attempt was made to grip with this foot.

The left hand gripped feebly, and this and all the other movements of this limb were very easily overcome. The condition was essentially the same as on examination a year before.

Post-mortem examination.—The brain was everywhere normal except in the region of the upper half of the fissure of ROLANDO in the right hemisphere, and in the left hippocampal region.

The lesion of the left hemisphere will be described subsequently (see Exp. 24*).

In the right hemisphere there was destruction of the cortex accurately limited to the upper half of the ascending frontal and ascending parietal convolutions.

The upper margin of the lesion was from 2 to 3 mms. distant from the longitudinal fissure, the edges of which were intact. The convex aspect of the superior frontal convolution, corresponding with the broad base of the superior frontal, was deeply eroded; and the grey matter was similarly eroded from the convexity of the ascending parietal convolution along the whole length of the intraparietal sulcus.

Between the two the fissure of ROLANDO was still visible, the grey matter at the depth of this not having been destroyed. The greater part of the postero-parietal lobule was intact, as well as the lower half of the ascending frontal, and lower extremity of the ascending parietal convolution (fig. 45).

The cranial nerves were intact, as well as the optic tracts and crura cerebri. The corpora quadrigemina and cerebellar peduncles were uninjured.

The right crus cerebri was seen to be very appreciably flatter than the left, especially at the middle of the *foot* of the crus. The right side of the pons was also flatter than the left.

The left middle peduncle of the cerebellum was somewhat less prominent than the right, but no perceptible difference could be made out between the right and left lobes of the cerebellum.

The right pyramid (fig. 46) was only half the size of the left, and slightly greyer in tint.

At the middle of the olivary body the transverse diameter of the right pyramid measured only 2 mms., while the left measured 4 mms.

The left half of the spinal cord was also only half the size of the right.

From the junction of the anterior with the posterior cornu to the surface of the lateral column the left measured 1.5 mm., while the right measured 3 mms.

The posterior columns were equal.

Transverse sections of the crura cerebri (fig. 47) showed that the middle

of the foot of the right crus was only half the diameter of the left, and stained more deeply with carmine—characteristic of sclerosis. The outer portion of the foot of the crus was however equal on both sides. Similar sections through the pons (fig. 48) showed the same relative reduction and sclerosis of the right pyramidal tracts.

(The figures are microphotographs of sections magnified about 8 diameters.)

In the spinal cord the secondary degeneration was still more striking. Sections through the cervical, dorsal, and lumbar regions (figs. 49, 50, 51) showed an extraordinary reduction and distortion of the left antero-lateral column. This was due to atrophy and contraction of the pyramidal tract or posterior part of the lateral column, from which the nerve-fibres had almost entirely disappeared, their place being taken by connective tissue staining deeply with carmine. The contraction had drawn the posterior horn to the left and forwards—particularly well seen in the dorsal region—and had so pulled upon the posterior column as to cause perceptible separation of the column of BURDACH from the column of GOLL. This is marked by a fissure visible in all the sections on the left, but not on the right side, or only very faintly. Though the left posterior column was distorted, its area was not reduced, as may be seen by examination of the sections.

Remarks.—This case shows that a destructive lesion implicating the cortex of the upper half of the ascending frontal and corresponding portion of the ascending parietal convolution causes marked and permanent impairment of voluntary motor power in the opposite limbs, the face being unaffected.

The sensibility of the paralysed limbs remained acute and to all appearance unimpaired.

The paralysed limbs, especially the leg which was most affected, exhibited in course of time the late rigidity or contracture with exaggeration of the tendon reactions, which is so characteristic of hemiplegia with descending sclerosis of the pyramidal tracts in man.

The sclerosis of the pyramidal tracts was in this case unusually well pronounced as far as the lumbar region of the cord. This was doubtless due to the long period that had elapsed since the establishment of the lesion—more than a year and a half. Hence the great shrinking of the degenerated tracts and consequent distortion of the spinal cord seen in the sections. It is further noteworthy that though in this case there was also an extensive lesion in the left hemisphere, but not in the motor area, no secondary degeneration existed on the right side of the spinal cord.

*Experiment 18** (Plate 25, figs. 52–55).

In this case the left hemisphere was exposed in the region of the fissure of ROLANDO, and the *ascending frontal and bases of the three frontal convolutions, and ascending parietal convolution were destroyed* by the galvanic cautery as far as could

be reached without actually exposing the extreme upper and lower extremities of these convolutions.

An hour after the operation the animal, in trying to move, fell over on the right side, the right arm and leg appearing quite helpless. At this time heat applied to the fingers and toes of the right and left side respectively caused equal signs of uneasiness.

Hearing and vision were unimpaired, the animal responding to sounds, and making gestures when approached.

Next day the right hemiplegia was very pronounced, the animal dragging the right limbs, moving on with the aid of the left hand and foot. There was visible, when the animal was drinking from a dish, a tendency of the head to the left side. At the same time also the eyes tended to the left. The animal was, however, able to move the eyes towards the right, but at rest they maintained a slight deviation towards the left side.

The right angle of the mouth was somewhat more open, and drooped a little, as compared with the left.

On the sixth day the animal was more active and more willing to move about than before. There was still some tendency to deviation of the head to the left, and the eyes did not seem to move so well to the right as to the left.

The animal was able to mount on its perch with the aid of its left hand and foot. It had great difficulty in getting its right foot on to the perch, but succeeded ultimately by hitching movements of its trunk. Slight power of flexion of the thigh and leg was visible.

During struggles also the right forearm would flex a little. The hand was not moved, and when the animal was at rest the arm was kept by the side semiflexed, and the fingers flexed over the thumb.

Slight weakness of the right facial muscles was still perceptible.

On the ninth day no tendency of the head or eyes to the left could be discovered, but the defective action of the right side of the mouth was still very perceptible when the animal grinned. With the exception of some power of flexion of the right thigh and leg, the right lower extremity was helpless. In struggling some shoulder movements of the right arm and flexion of the forearm occurred, but no volitional use of this arm was seen. The right patellar reaction was more distinct than the left.

On the fourteenth day the condition of the limbs was essentially the same, but the facial paralysis on the right side was not very perceptible, though food seemed to accumulate more readily in the right cheek-pouch than the left.

Three months after the operation the animal, in moving about, was able feebly to flex the right thigh and leg so as to lift the foot clear of the ground, but the foot had not moved on the ankle. It carried the right arm by the side semiflexed; occasionally, in struggling with the left side, making some shoulder movements of the right arm, and slight flexion of the right forearm. Occasionally also the fingers of the right hand were seen to flex under the same circumstances, viz.: associated with

similar action of the left. The slightest touch on the limbs attracted the attention of the animal as much on the right side as the left.

Four months subsequent to the operation the condition was essentially the same, the associated movements of the right arm and fingers being frequently seen along with similar vigorous movements of the left arm. No volitional movement, prehension, &c., had ever been made with the right arm. The foot was lifted en masse with the leg when the animal moved about.

Six months after the operation the associated movements of the right arm were sometimes seen in a very remarkable manner. When the animal scratched itself vigorously with the left hand, a similar scratching action was initiated on the right, and this was frequently continued for a distinct interval after the left had ceased. The scratching with the right hand was made in the air, and quite without purpose.

Seven months after the operation the pliability of the right leg to passive movements was somewhat diminished, and there was a tendency to equino-varus when the leg was fully extended. There was no marked rigidity of the right arm, though the thumb when straightened readily returned to its position of flexion on the palm. The fingers could be straightened without causing great tension of the flexors. The animal was exhibited before the Physiological Section of the International Medical Congress of 1881, nearly eight months after the operation :—

“The movements of the leg were seen to be greatly impaired, and the arm quite powerless, being maintained flexed at the elbow, the thumb bent on the palm, and the fingers semiflexed.”*

The animal was killed with chloroform, and a committee was appointed to examine and report on the condition of the brain, along with that of a Dog exhibited by Prof. GOLTZ at the same time.

A photograph was taken of the brain, which is here given (Plate 25, fig. 52). As it was not considered very satisfactory, a drawing was made and a woodcut, which will be found in vol. 1, p. 243, of the Transactions of the Congress.

A preliminary account of the brain was also given by Prof. SCHÄFER, and a more extended and corrected report has been since published by him in the ‘Journal of Physiology,’ vol. 4, Nos. 4 and 5. The region destroyed comprised: “The ascending frontal convolution except a very small portion of the upper end next the great longitudinal fissure and except also at its lower end; about one centimeter in length, or nearly one-third of the whole length of the convolution, here remaining intact. The posterior third of the upper division of the anterior portion of the (frontal) lobe, the lower division remaining untouched.

“In the parietal lobe: the greater part of the ascending parietal convolution, only about 5 mms. at the upper end, and 6 mms. at the lower end remaining. A small piece of the parietal lobule. Rather more than the half (longitudinally) of the ascending limb of the angular gyrus, and of the supramarginal convolution.

* Transactions of the Int. Med. Congress, 1881, vol. I, p. 237.

“The other lobes are not encroached on by the injury, nor is the internal surface of the hemisphere, although, as will be explained presently, it is probable that by an undermining process of secondary nature, a portion of the marginal convolution may have been cut off from continuity with the central parts of the cerebrum.”

The area of destruction was covered by adherent dura mater, under which was a secondary cavity, but the whole lesion was external to the central ganglia.

Microscopical sections of the brain demonstrated the existence of secondary degeneration in the left internal capsule, in the foot of the crus cerebri, anterior pyramid, and at the upper part of the cervical cord, in both pyramidal tracts.

In the lower cervical, dorsal, and lumbar regions of the cord, sections by Dr. FERRIER (Plate 25, figs. 53, 54, 55) demonstrated the existence of secondary degeneration only in the pyramidal tract of the right side of the cord. Slight contraction and consequent distortion had also occurred here as in the previous case—Experiment 17*, but the changes were much less marked, probably due to the relatively much shorter period that had elapsed between the lesion and death.

Remarks.—The lesion in this case implicated the whole of the so-called motor area more or less, the centres for the leg and face being only partially destroyed. As a result there was motor hemiplegia of the opposite side, with temporary conjugate deviation of the head and eyes, partial facial paralysis, and incomplete paralysis of the leg.

The hemiplegia was of a permanent character, as was evidenced by the commencing contracture or late rigidity, and the demonstration of secondary degeneration in the pyramidal tracts. The animal, except for the right hemiplegia, was in other respects perfectly normal. There was no affection of the special senses, and there was no discoverable impairment of sensation in the paralysed limbs to touch, or any form of painful stimulation, heat, pinching, &c.

General Results.

These experiments show that destructive lesions of the cortical areas, irritation of which by electrical stimuli causes definite movements on the opposite side, cause motor paralysis without loss of sensation, limited (monoplegia), or general (hemiplegia), according to the position and extent of the lesion. The degree of paralysis varies with the completeness of destruction of the grey matter of the respective centres. It is further seen that destructive lesions limited to the cortex and subjacent medullary fibres of the Rolandic zone give rise to secondary degeneration (sclerosis) of the pyramidal tract, traceable from the seat of lesion in the internal capsule, crus cerebri, and anterior pyramid of the same side, and in the postero-lateral or pyramidal tract in the opposite side of the spinal cord.

SECTION IV.

LESIONS OF THE FRONTAL LOBES.

Experiment 19 (Plate 25, fig. 56).

In this animal, which was very vivacious and intelligent, the frontal lobes were exposed on both sides. Faradic stimulation of the base of the first and second frontal convolution on the left side was found to cause movement of the head and eyes to the right. This region, viz.: *the base of the superior and middle frontal convolutions, was then seared with the cautery, first on the left, and then on the right side.* On the animal recovering consciousness, which it did after the dressing of the wound was finished, it sprawled with all four limbs, and opened both eyes. The pupils were contractile to light, but the right was somewhat smaller than the left.

Half an hour after the operation the animal was able to sit up, which it did holding the head bent on the chest. There was no distortion of the head. An hour after the operation it was able to move about freely and to climb up the bars of the cage, hand over hand. It started at sounds but did not turn the head or eyes, except perhaps slightly to the right, when sounds were made close to each ear respectively.

The head shook when the animal stooped, and there appeared to be a want of power to turn the head without the body as a whole.

An hour and a half after the operation the animal wandered about restlessly, and when it sat still the head oscillated—nutation. Sight was unimpaired. The slightest touch on any part of the head, neck, or other part of the body caused the animal to put its hand to the spot, showing unimpaired tactile sensibility. It started to sounds made to the right or left, but did not look round as other Monkeys do under similar circumstances. In turning it described a considerable circle, evidently from defective mobility of the head and eyes laterally.

Next day there was some œdema of the eyelids so that the eyes could not be seen distinctly. Tapping close to the ears caused them to twitch, but the animal did not look round, except perhaps slightly to the right. Tactile sensibility of the head and neck was as acute as elsewhere, the animal always putting its hand up to the place touched.

The animal was very dull and listless, paying no attention to its surroundings, or occasionally running about in an aimless manner.

On the fourth day the condition was essentially the same. But to-day it was seen to turn its head both to the right and left without turning its body as a whole. The eyeballs were not fixed but moved about in various directions. The movements of the limbs were in every respect perfect.

There were at this time indications that the wound was not aseptic, which was attributed to the fact that the anterior extremity of the wound was not sufficiently protected by the dressings.

On the fifth day the animal passed into a state of coma, in which condition it died.

Post-mortem examination.—On removal of the dressings pus was found exuding from the edges of the wound. The antiseptic arrangements had failed by reason of the difficulty of protecting the anterior extremity of the incision.

The seat of lesion in both frontal regions was covered by a layer of pus. There was no adhesion of the dura mater, except slightly at the posterior margins of the lesions, but there was general hyper-vascularity of the pia mater. There was however no effusion at the base, or sign of suppuration except in the frontal regions as before described.

On removal of the brain the anterior extremities of the frontal lobes with the olfactory bulbs and tracts, and the orbital lobules were found to be quite normal; free from signs of inflammation. All the cranial nerves were intact.

The convex aspect of each frontal lobe was the seat of an oval depression, caused by loss of substance and suppuration, of almost precisely equal extent, but not quite symmetrical as to position.

On the left the lesion occupied the whole of the middle frontal convolution from the precentral sulcus to the orbital margin, and invaded the middle of the superior frontal convolution up to within $\frac{1}{8}$ th of an inch of the longitudinal fissure, leaving a triangular portion of the base, and a corresponding portion of the anterior extremity uninjured. The middle portion of the inferior frontal convolution was also involved in the lesion, while the posterior and the anterior extremities were uninjured.

On the right side the margin of the oval shaped lesion extended slightly farther back into the base of the superior and middle frontal convolutions than on the right, but did not come so close to the longitudinal fissure. A triangular portion—the base posteriorly—of the superior frontal convolution along the margin of the longitudinal fissure was intact. The narrowest portion of this measured $\frac{1}{4}$ inch across.

The inferior frontal convolution was represented only by a portion of the base, and a small apex anteriorly.

Remarks.—This case was unsuccessful in a surgical point of view, the antiseptic arrangements having been imperfectly carried out, hence suppuration and complication of the phenomena ascribable to the experimental lesions.

But there was plainly in the first instance, before such complications occurred, as the result of destructive lesions of the regions,—electrical irritation of which causes movements of the head and eyes to the opposite side—[centre 12 (FERRIER)]—abolition or great impairment of the lateral movement of the head and eyes, and instability of the head and neck, all other movements being unimpaired. There was no defect in tactile sensibility in the head and neck or other part of the body, or in the faculties of special sense. The mental aspect of the lesions was general apathy as regards surroundings, varied by aimless restlessness.

Notwithstanding the further extension of the original lesions by inflammation and

suppuration, the lateral movements of the head, and movements of the eyeballs, were seen before the animal passed into the state of semi-coma preceding death.

Experiment 20 (Plate 25, fig. 57).

In this animal the frontal lobes were exposed on both sides anterior to the pre-central (antero-parietal) sulcus, and the convexity of both lobes in advance of this sulcus generally seared and broken up by the galvanic cautery.

On regaining consciousness immediately after the dressing of the wound, the animal was able to open both eyes and to make sprawling movements with its limbs.

Half an hour subsequently it was seen, in trying to walk, to sprawl along on its ventral surface, as if unable to keep its head up. It was able, however, when it came to the bars of the cage to sit up and try and climb.

An hour after the operation it was seen, in climbing up the bars of the cage, to let its head drop between the bars as if powerless, and it did not turn its head or eyes to either side when touched or when sounds were made, though it evidently, by its general movements, both felt and heard.

When the animal was sitting up, which it could do quite well, the head was held in the natural position, not drooping and not shaking or oscillating.

Next day the animal seemed in perfect health, running about restlessly hither and thither. There seemed no defect in the power of carrying its head, or in turning its head and eyes to either side without turning the trunk. The general motor powers were unimpaired. Tactile sensibility in the head and neck and elsewhere appeared perfectly normal; and sight, hearing, and the other faculties of sense also unimpaired.

No physiological deficiency could be discovered.

On the third day the condition was the same. The animal was in the most constant state of activity and restlessness, running about incessantly, and fumbling about among the straw, &c., at the bottom of the cage.

Next day it was watched for a long time, but no defect could be ascertained as regards its motor or sensory faculties. Occasionally it would sit still looking vacantly, but most commonly it was engaged running about restlessly, or fumbling at the bottom of the cage.

No further change was seen during daily observation for ten days after the operation, the animal continuing in the same alternately dull and restless condition.

The weather at the time was intensely cold, and without any other discernible cause than this the animal died eleven days after the operation.

Post-mortem examination.—The edges of the wound in the scalp had not healed, but there was no suppuration or effusion. There was no effusion or sign of inflammation within the skull, and the brain was everywhere normal except in the frontal region.

On the *left* side the cortex was entirely destroyed over the anterior two-thirds of

the convex aspect of the superior frontal convolution. The tip of this had been almost entirely severed by a transverse incision, which did not however extend to the orbital aspect. The mesial aspect of this convolution was also uninjured. The cortex was also deeply eroded, but not entirely removed, over the whole extent of the middle frontal convolution, except at the base; and the inferior frontal convolution was also almost entirely destroyed, the base remaining uninjured.

On the *right* side the middle frontal convolution was almost entirely destroyed, a small portion of the base immediately adjoining the precentral sulcus still remaining. Though the superior frontal convolution still retained the cortex for a breadth of a quarter of an inch external to the longitudinal fissure, yet it was undermined by severance of the medullary fibres almost close up to the longitudinal fissure.

The base of the inferior frontal convolution was uninjured, but the rest was entirely destroyed.

The orbital aspect, with the olfactory tracts and bulbs, was free from lesion, though the orbito-frontal margin was ragged and eroded.

Remarks.—This case was also unsuccessful as regards long duration of observation, but it is instructive as showing that destruction of the greater portion of the cortex of the frontal lobes anterior to the precentral sulci, though at first causing great impairment of the movements of the head and eyes, particularly in a lateral direction, does not permanently render these impossible. For already on the second day after the operation, movements of the head and eyes to either side were seen without any appearance of stiffness or turning of the trunk. The lesions, however, did not implicate the whole of the regions irritation of which causes lateral movements of the head and eyes.

There was no defect of motor power other than of the head and eyes immediately after, or at any time subsequent to the lesion; and common and special sensibility were unimpaired. The curious purposeless restlessness before observed was also very evident in this case, alternating with general dulness and apathy.

Experiment 21 (Plate 25, figs. 58, 59).

In this animal—a large dog-faced Monkey—the frontal regions were exposed in both hemispheres, and severed by the galvanic cautery by a transverse incision just anterior to the precentral sulcus. *Both frontal lobes were removed bodily.*

An hour after the operation the animal lay with its eyes shut, but partially opened them when disturbed, and made spontaneous sprawling movements with all four limbs. Sensibility was evidently retained all over the body, as it moved or grunted if slightly pinched anywhere.

Ammonia held before its nostrils caused it to snort or sneeze.

An hour after the operation it would start at sounds, opening its eyes feebly, and also if touched anywhere on the trunk or limbs. The right arm and leg did

not seem to act with so much vigour as the left in its spontaneous movements. It was unable to sit up.

Next day the animal was found in a sort of dozing condition, but opened its eyes when called to, or if touched anywhere. It was able to move all four limbs energetically and grip firmly with both hands and feet. It was also seen to move its head backwards and forwards. It could extend its trunk, but was unable to sit up. It could also move its tail, and its facial muscles were seen to act normally when the animal grinned, which it did if disturbed.

The animal died suddenly when being fed.

Post-mortem examination.—Examination showed that the cause of death was a recent hæmorrhage which filled the anterior fossa of the skull, and extended to some extent over the convexity of the hemispheres, and towards the base of the brain.

Both frontal lobes had been completely removed by a frontal or transverse vertical incision immediately anterior to the precentral sulcus on each side. The base of the superior frontal convolution, and a small portion of the base of the middle frontal convolution at the upper bend of the precentral sulcus still remained intact however.

The whole of the frontal lobes in advance of this had been divided down to the orbital surface, the incision being just anterior to the optic commissure, which, with the optic nerves, was uninjured. The olfactory tracts had also been severed, less completely on the left than the right.

The temporo-sphenoidal lobes were intact. On the surface of the plane of section were clearly seen the divided anterior portion of the corpus callosum, and the head of the corpus striatum which was cut somewhat further back on the left side than on the right.

Remarks.—Notwithstanding the formidable character of the operation, life might have continued but for fatal secondary hæmorrhage. The amount of recovery within an hour of the operation was very remarkable.

The animal retained consciousness, was able to make volitional movements with all four limbs, though owing to the greater amount of lesion in the left hemisphere, the right limbs were not so strong as the left. Vision was retained, as well as hearing and tactile sensibility. The facial movements were unimpaired.

The only defect observed was the inability of the animal to move its head laterally or sit up, though it was able to extend the head and trunk.

Experiment 22 (Plate 26, figs. 60–73).

In this animal both frontal lobes were exposed towards their anterior extremities, the middle frontal sulcus being visible in the centre of the exposed region. The tip of the frontal lobes could be reached and raised with the handle of a scalpel.

Electrical exploration was made of the exposed frontal lobe on the right side. Irritation at the base of the superior and middle frontal convolutions—centre 12 (FERRIER)—caused movement of the head and eyes to the left.

More anteriorly stimulation seemed frequently associated with movements of the eyeballs to the opposite side, but they fluctuated so that occasionally doubt was entertained. But there was no action whatever of the head or trunk.

Unless the movements of the eyeballs were directly caused by irritation, the results of electrification of the prefrontal lobes must be set down as negative to all external appearance.

The whole convex surface of the prefrontal lobes, in advance of centre 12, was then cauterised with the galvanic cautery. The mesial aspect of these regions was also cauterised; the anterior part of the falx being divided and tied so as to allow of this being done as effectually as possible. Anteriorly the destruction was effected as far forward as could be done without injury to the olfactory bulbs. The orbital aspect of the lobes was slightly raised so as to allow of complete destruction of the lower frontal convolution.

The cauterisation thus implicated the anterior two-thirds of the three frontal convolutions, so far as could be determined before death.

When the dressings had been applied the animal continued for a short time to have muscular twitchings, as if from some irritation of the dura mater, but in little over an hour was able to sit up and walk a few steps, though rather shaky. It was able to open its eyes, and it withdrew its hands and feet when they were touched.

A touch on the right ear caused movement of the head to the left, and a touch on the left caused movement to the right.

Next day the animal seemed perfectly recovered. It ran about actively; took things offered it with the utmost precision. Particular attention was paid to the movements of the head and eyes. These were evidently retained in their integrity, for the animal turned its head to either side without moving its trunk, and forwards and backwards with perfect freedom. Hearing was acute and tactile sensibility unimpaired everywhere. Smell was retained, judging from the apparent pleasure excited by oil of bergamot placed under its nostrils. Ammonia excited active signs of irritation in the nostrils.

No physiological defect could be discovered. Nor could any very definite alteration in the animal's mental character be determined. It seemed only less timid of its companion, and persisted in stealing food out of its hands, though punished every time with an angry bite or a tug. But from this time onwards till its death by chloroform, eleven weeks after the operation, it continued in perfect health and exhibited no perceptible deviation from the normal.

Post-mortem examination.—The orifices in the skull in the frontal region were covered by membrane continuous with the dura. The dura stripped readily without trace of adhesion, everywhere except at the seat of lesion in the prefrontal lobes.

It was found on removal of the brain that the olfactory bulbs and tracts were uninjured. These were removed intact, and without any signs of adhesion.

Examination of the brain after removal of the adherent membrane revealed an

almost complete obliteration of the prefrontal lobes. Except a minute portion of the frontal extremities overlying the olfactory bulbs and the base of the superior and middle frontal convolutions (centre 12), all the intervening portion of the superior, middle, and inferior frontal convolutions had been destroyed, the destruction involving the orbito-frontal margin of the hemispheres as far as the central point of the triradiate fissure.

Owing to the contraction caused by cicatrisation, the uninjured frontal apices came within a quarter of an inch of the anterior margin of the posterior third of the superior frontal convolutions which remained intact. For the same reason the orbital aspect of the hemispheres was tilted upwards and backwards to a considerable extent (fig. 60).

Microscopical examination.—The brain after being sufficiently hardened in alcohol was cut in a series of frontal oblique sections, parallel to the direction of the fissure of ROLANDO. They were stained with carmine, and sun-prints taken of sections at different levels from before backwards. They are seen on Plate 26, figs. 61 to 71. Figs. 72 and 73 are transverse sections of the medulla oblongata at the upper and middle of the pyramids respectively.

Fig. 65 first shows clearly a condition, which is more obscure in the preceding sections, of sclerosis of the lowermost and innermost fibres of the crescentic shaped section of the internal capsule. The sclerosed parts being more deeply stained by carmine come out a lighter shade in the sun-prints. They are situated here on each side of the oblique section of the third ventricle. In fig. 66, which is essentially the same as fig. 65, the lighter sclerosed portions are seen in the same position. In fig. 67, behind the optic commissure, the patches occupying the same relative position are situated nearer the base. In fig. 68 they occupy the innermost part of the foot of the crus, and so in figs. 69 and 70 somewhat further back.

Fig. 71 is a section just at the emergence of the crura from the anterior aspect of the pons, and owing to the obliquity of the section the anterior margin of the pons bridges over the space between the crura. The section does not show so well as the former ones, being cut on somewhat a different plane and not so well stained. But at the innermost margin of the crus the sclerosis is still more or less apparent, being indicated by the white patches. The sclerosed patches were visible in all the sections as far as the crura cerebri, but they could not be traced beyond. Whether the bundles turned up into the corpora quadrigemina or became lost in the pons I have not been able to determine.

But as Sections 72 and 73 show, there was no sclerosis visible in the anterior pyramids of the medulla oblongata.

Remarks.—No cerebral lesion could well have been more latent or devoid of symptoms, either physical or mental, than this.

There was no discoverable sensory or motor defect, and no determinable psychological alteration. Yet the prefrontal lobes on both sides were destroyed to a very great extent. But the bases of the three frontal convolutions, irritation of which region

causes the movement of the head and eyes to the opposite side, were practically intact.

But though as regards discoverable symptoms the case was negative, the microscopical investigation of the brain revealed facts of great importance both as regards the anatomical relations and probable physiological significance of the prefrontal cerebral regions.

The sections demonstrate the occurrence of secondary degeneration or sclerosis of certain fibres of the internal capsule and crura cerebri. These occupy the lowermost and most internal aspect of the transverse sections of the internal capsule, and the most median bundles of the foot of the crus cerebri. The further destination of these bundles, whether they end in the corpora quadrigemina or in the pons, was not determined. But the facts demonstrated show that the prefrontal regions are anatomically in connexion with the median bundles of the foot of the crus and corresponding fibres of the internal capsule.

Experiment 23 (Plate 27, figs. 74-86).

In this animal the frontal lobes were exposed on both sides, and the cortex cauterised extensively towards the base of the three frontal convolutions. When this was done first on the left side the eyes were seen to be deviated to the left. On the right side the destruction was somewhat less extensive. In less than an hour after the operation the animal was able to sit up and move about spontaneously, keeping its head down and its eyes shut. No further observations were made at this time. Next day the animal was found resting on its perch in a drowsy condition with its eyes shut and taking no notice of anything. But when a piece of apple was held under its nose, it at once put up its hand to seize it—smell being evidently retained. Tactile sensibility was also acute everywhere, as it moved if touched on the head, or on its hands or feet. It turned its head upwards and to the right when the right ear was tickled; and it frequently shook its head from side to side as if to remove irritation.

The eyes being forcibly opened were seen to have a normal position, and the pupils of moderate size.

Attention was suddenly excited by the attendant offering it the yolk of an egg. This it devoured with evident gusto.

On the third day the same dreamy or drowsy condition was maintained, except when food was offered it, when it always exhibited interest. All its motor powers were perfect, and it turned its head alternately to the right and left, following an apple which was moved in front of it. Sight, hearing, smell, and taste were retained.

On the seventh day the animal was still very dull, taking no interest in anything but its food, which it evidently enjoyed heartily. The movement of the head and eyes to either side was plainly observed without the slightest turning of the trunk. All its motor powers otherwise, and sensory faculties, were unimpaired.

Except for general dulness and want of interest in its surroundings, the animal exhibited no perceptible effect of the operation, and continued in excellent health.

Seven weeks after the operation chloroform was again administered, and the membrane covering the orifices in the frontal regions incised and the fronto-orbital margins of the hemispheres scooped out so as clearly to expose the roof of the orbits—the middle line and region of the olfactory bulbs being avoided.

On the animal regaining consciousness, which it did very speedily, the head was observed to be in a state of rapid lateral oscillation, as rapid as the tremor of paralysis agitans. Within half an hour after the operation, while the lateral oscillation was continuing, the animal was able to climb up the bars of the cage hand-over-hand, holding the head well back and the trunk stiff. The right eyelid was observed to droop considerably.

Tactile sensibility was unimpaired generally.

An hour after the operation the tremor of the head was almost gone, and the animal occasionally made circus movements, pivoting itself on the buttocks, and turning round with the head en masse with the trunk.

But within two hours some indications were seen of lateral movements of the head alone, apart from the trunk.

Next day the animal was as usual dull, but opened its eyes if touched anywhere or called to. The right eyelid still drooped perceptibly. It moved its head freely backwards and forwards, and also apparently to both sides. It was seen to shake its head vigorously from side to side, as if to remove itching. Sight was perfect, as also hearing, tactile sensibility, and to all appearance also smell, as it at once grabbed at a piece of apple held under its nostrils.

On the following day free movement of the head and eyes in every direction was clearly manifested, and from this time onwards it was impossible to discover any appreciable effect of the operation. The animal was killed with chloroform two months and a half after the first operation.

Post-mortem examination.—Except over the prefrontal regions the membranes stripped readily without any sign of inflammation.

On removal of the brain it was found that the olfactory tracts and bulbs were uninjured.

The only lesion was in the frontal lobes (fig. 74).

On the *left* side the cortex at the base of the superior and middle frontal convolutions was irregularly eroded, while the base of the third frontal was intact. The mesial surface of the superior frontal was also intact as far as the anterior extremity, a minute portion of which overlying the olfactory bulb was also uninjured. But the anterior two-thirds of the middle and inferior frontal convolutions and the orbito-frontal margin of the hemisphere had been destroyed.

On the *right* side the superior frontal convolution was intact, as well as the mesial

aspect of this convolution, all along the longitudinal fissure; but at the anterior extremity it became distorted towards the left side.

The base of the inferior frontal convolution also remained; but the middle frontal was obliterated, its place being indicated by a surface sloping obliquely downwards and forwards from the precentral sulcus to the centre of the triradiate sulcus in the orbital aspect of the hemisphere. The anterior two-thirds of the inferior frontal convolution were also entirely removed.

There was thus lesion, without entire destruction, of the posterior third of the three frontal convolutions, with complete removal of the anterior two-thirds of the inferior and middle, and portions of the superior frontal convolutions, on the left side; and complete removal of the middle frontal, and anterior two-thirds of the inferior frontal convolution on the right side.

Microscopical examination.—A series of sections was made of the brain (hardened in bichromate of ammonia) from before backwards parallel to the fissure of ROLANDO, or at right angles to the crura; and also transverse sections of the pons and medulla. (A series of sun-prints of these arranged from before backwards is given in Plate 27, figs. 75–86.)

At the lower internal margin of the crescentic-shaped section of the internal capsule, precisely corresponding to the position of the sclerosed patches in Experiment 22, specially well seen in figs. 76 and 77, some of the bundles were deeply stained, and therefore appear light in the prints, while others internal to these were less stained than the normal, and therefore appear as dark patches in the prints.

In the sections of the crura (figs. 79–82) the median or most internal bundles of the foot of the crus were most deeply stained, and in some of the sections there was an appearance as if some of these bundles took a direction upwards towards the region of the aqueduct of SYLVIUS (figs. 79 and 81).

In sections of the upper part of the pons some bundles were seen more deeply stained than the others. They occupied the same relative position to the rest of the fibres of the pyramidal tracts as in the crus and internal capsule, viz., the mesial aspect. But these deeply-stained bundles could not be traced beyond the pons, and could not be seen in the sections of the medulla oblongata (figs. 83–86).

Remarks.—In this experiment there occurred at the moment of cauterisation of the base of the superior and middle frontal convolutions, a conjugate deviation of the eyes to the same side. This was also observed in another case, not here reported in detail owing to the animal having died soon after the operation without having regained consciousness.

But notwithstanding the extensive lesions at the base of both frontal lobes, no physiological defect, either sensory or motor, persisting the day after the operation, was at all appreciable. Whether at this time the movements of the head and eyes were deficient was not clear, but on the third day it was plain that these were capable of being effected to all appearance in a perfectly normal manner.

The subsequent destruction of the prefrontal regions caused symptoms which, though very transient, were yet of important significance. These were rapid lateral oscillations of the head, lasting only a few hours, apparent inability to move the head except en masse with the trunk, and ptosis of the right eye. None of these symptoms were, however, at all discoverable on the third day, and from this time onwards the animal exhibited no discoverable defect, either as regards the movements of its head and eyes, or otherwise. It is to be noted in this case that a considerable portion of the base of the superior frontal convolutions still remained uninjured, though the prefrontal regions were almost entirely destroyed.

Apart from a degree of dulness or apathy—and this as time went on not particularly observable—there was nothing in the animal's behaviour at all remarkable or appreciably abnormal.

But the important anatomical fact described in connexion with Experiment 22 was here also noted, viz. : descending degeneration of the mesial bundles of the internal capsule and crus cerebri, as far as the pyramidal tracts of the pons.

These degenerated fibres were, in the internal capsule, of clearly different dates. The older, which were sclerosed and deeply stained, might reasonably be regarded as in relation with the older of the lesions in the frontal lobes, viz. : those at the base of the frontal convolutions ; while the others situated nearer the middle line and less deeply stained than normal, might reasonably be connected with the later prefrontal lesions. Their position agrees exactly with that of the degenerated bundles in connexion with the prefrontal lesions of Experiment 22.

The ultimate destination of the degenerated tracts was not determined, but they do not appear to pass into the anterior pyramids of the medulla oblongata.

General Results.

These experiments on the frontal lobes show a remarkable absence of any discoverable physiological symptoms in connexion with the almost entire destruction of the prefrontal regions, or anterior two-thirds of the frontal convolutions ; and only temporary impairment or paralysis of the lateral movements of the head and eyes as the result of lesions, extensively destroying the cortex at the base of the superior and middle frontal convolutions (centre 12). In none of the cases, however, was the destruction of this centre on both sides quite complete. It was most extensive in Experiment 21, in which also the prefrontal regions were removed.

This case, however, owing to the sudden death of the animal shortly after the operation, did not afford much opportunity for observation of the effects of the lesion.

But negative facts of great importance were demonstrated in this case. There was no affection of sensation general or special, and the limbs, face, and tail were capable of voluntary movement.

There was apparent total paralysis of the lateral movements of the head and eyes, and inability to maintain the upright position, though backward and forward move-

ments of the head were seen, and also extension of the trunk. In this case also in addition to the frontal regions, portions of the head of the corpus striatum was removed on both sides, more on the left than right.

The facts of Experiment 23 show that extensive lesion of the prefrontal lobes, subsequent to the time when all effects of destructive lesions at the base of the frontal convolutions had disappeared, caused for a time disorders in the movements of the head—shown in lateral oscillation of the head, and apparent inability to turn the head and eyes.

There was also in this case a phenomenon not observed in any other case, viz.:—ptosis of the right eyelid. There was no local injury perceptible to account for this, but whether it was the direct result of the prefrontal lesions is a point that may be questionable. The facts of this experiment taken with those of Experiments 19 and 20 render it probable that the prefrontal lobes have essentially the same physiological relations as the electrically effective postfrontal centres.

In Experiments 19 and 20, notwithstanding the extensive destruction of the post-frontal centres, the paralysis of the lateral movements of the head and eyes was very transitory, and in Experiment 23 the destruction of the prefrontal regions subsequent to the recovery from the lesions of the post-frontal centres re-induced similar symptoms. Hence it would appear that so long as portions of the frontal centres remain intact, the movements of the head and eyes are not permanently paralysed.

The prefrontal and postfrontal regions are shown by the secondary degenerative changes demonstrated in Experiments 22 and 23, to be anatomically related to the same tracts of the internal capsule and crus cerebri. This fact also would indicate community in their physiological relationships. Though the prefrontal regions did not react, or very doubtfully, to electrical stimulation, yet this would not militate against their being considered part of the same physiological centre as the postfrontal regions. For it was found that the occipital lobes did not respond like the angular gyri to electrical stimulation, and yet formed an integral portion of the visual centres. As to the psychical effects of the frontal lesions it is difficult to speak at all definitely. In some cases there was no very marked change, yet in others, as in Experiment 2, previously carefully studied, there was a very manifest alteration in the character of the animal.

On the whole there seemed mental deterioration, characterised by general apathetic indifference or purposeless unrest: effects which, in comparison with those of other lesions, appear to have special relation with lesions of the frontal lobes as such.

SECTION V.

LESIONS OF THE HIPPOCAMPAL REGION.

In none of the experiments recorded in the preceding sections relating to lesions in the occipital, parietal, frontal, and external convolutions of the temporo-sphenoidal

lobes, was any defect discoverable in the domain of tactile or general sensibility. I had in my previous researches (*Philosophical Transactions*, Vol. 165, Part 2) arrived at the same results, and I described how, after various experiments in which the hippocampal region—including in this the cornu ammonis and gyrus hippocampi or uncinata gyrus—became implicated in destructive lesions, and in which impairment or abolition of tactile sensibility was observed, experiments were devised with the view of destroying this region primarily. The method adopted was to pass a wire cautery through the extremity of the occipital lobe downwards and forwards in the direction of the hippocampal region. In two of the experiments, XVII. and XVIII., tactile sensibility was almost if not entirely abolished after this operation; in the latter case directly, and in the former, in which the hippocampal region became implicated in the destructive softening, on the third day after the operation.

As the validity of these experiments has been disputed on the ground that the posterior or sensory division of the internal capsule may have been involved in the lesion, I have re-investigated the position and extent of the lesions in these cases, the brains having been carefully preserved in spirit.

Before the brains were cut in sections, drawings were made by Mr. COLLINGS of the appearances presented by them.

Plate 28 shows photographs of the drawings of No. XVII.; fig. 87 being a drawing of the anterior half of the left hemisphere, and fig. 88 being the appearance presented by the under surface. In fig. 88, the point of emergence of the cautery is well seen—quite external to the gyrus hippocampi; and in fig. 87, the total breaking down of the hippocampal region is indicated. On the upper surface of the lateral lobe of the cerebellum is a superficial groove indicating where it was grazed by the cautery.

Figs. 89–94 are a series of sections of the hemisphere, cut transverse to the antero-posterior axis, arranged from behind forwards, beginning with the posterior cornu of the lateral ventricle, and ending with the head of the corpus striatum and anterior extremity of the temporo-sphenoidal lobe. Not a trace of the hippocampus major was found in any of the sections, and the gyrus hippocampi where it remained was in the form of a thin shell. All the medullary fibres of the hippocampal region, and also of the inferior temporo-sphenoidal convolutions were broken down and fell as débris out of the sections. The medullary fibres passing into the superior temporo-sphenoidal convolution were not destroyed, but they frequently broke through as seen in figs. 91 and 92 during the cutting and mounting the sections.

But the internal ganglia,* the crus cerebri with the section of the optic tract, and the internal capsule were absolutely uninjured, as may be seen in the various sections. Only those fibres descending towards the hippocampal and inferior temporo-sphenoidal regions were destroyed, and the corresponding fibres of the posterior cornu.

The drawings in figs. 95 and 96 represent the under surface of the posterior half of

* The whitish spots seen on the lenticular nucleus in fig. 93 are caused by portions of paraffin used for embedding adhering to the edges of the section and slipping underneath in mounting.

the right hemisphere of XVIII., showing the point at which the cautery entered the extremity of the occipital lobe, and the groove which it made immediately internal to the collateral fissure; and the frontal aspect of the same portion of the brain, showing the track of the cautery in the lower and inner temporo-sphenoidal region. Figs. 97-102 are a series of frontal sections of the hemisphere from the occipital to the anterior portion of the temporo-sphenoidal region. In figs. 97 and 98 the walls of the calcarine fissure are seen to be completely broken up. Figs. 99 and 100 show total disorganisation of the medullary fibres of the lower temporo-sphenoidal region and complete disappearance of the cornu ammonis. The gyrus hippocampi is represented by only a thin shell of cortex possessing no medullary connexions.

Figs. 101 and 102 were stained with logwood, and therefore do not show so well as prints. In these sections there are still remnants of the hippocampus, and some of the medullary fibres of the superior temporo-sphenoidal convolution are involved in the lesion. But with the exception of some lesion of the base of the lenticular nucleus, seen in fig. 102, the area of destruction was entirely clear of the central ganglia and internal capsule. The crus cerebri was absolutely uninjured.

It will thus be seen that there are no grounds for attributing the tactile anæsthesia observed in these two experiments to destructive lesion of any other part of the hemisphere than the cortex and medullary fibres of the hippocampal and lower temporo-sphenoidal region. The profoundness of the anæsthesia exhibited in these two cases was indicated by the almost total absence of any sign of sensation to thermal stimulation of the severest form on the side opposite the lesion.

In Experiment XVII., in which the track of the cautery swerved away from the hippocampus, anæsthesia was not observed until by the secondary softening the hippocampal region, as shown in the sections, became involved. In this it was noted that there were some indications of basilar meningitis, but there was no softening or destructive lesion of any part of the brain except that of the hippocampal and lower temporo-sphenoidal region described and figured.

These experiments were made without antiseptic precautions, and therefore the exact limitation of the primary lesions could not be ensured, owing to secondary inflammation which invariably set in. And this is a fact which must always be reckoned with in estimating the effects of cerebral lesions made without antiseptics.

It is altogether impossible to reach and destroy the hippocampal region without causing injury to some other parts of the brain, and it is necessary to eliminate the effects attributable to these by previous experiments.

In the experiments about to be related the hippocampal region was injured or destroyed as in former experiments by heated wires or other cauteries, pushed through the occipital lobe downwards and forwards along the hippocampal region, or guided along this region by a director inserted between the under surface of the occipital lobe and the tentorium cerebelli; or by means of incisions from the convex aspect of the temporo-sphenoidal lobe so calculated as to direction and depth as to sever the

hippocampal and lower temporo-sphenoidal region from the rest of the hemisphere without injury to the crus cerebri or other structures.

Many of the experiments were unsuccessful owing to miscalculation of the direction and depth of the lesions and consequent injury of the basal ganglia or crus cerebri. These it is not considered necessary to report, as any lesion of this kind was regarded as vitiating the whole experiment.

In the others, all of which are reported, varying success was met with as regards the degree and limitation of the lesion to the hippocampal region. Unfortunately the mortality has been such as to interfere with the solution of some points of importance in connexion with the permanency of the effects of total destruction of the hippocampal region and its secondary results.

*Experiment 24** (Plate 29, figs. 103--109).

The subject of this experiment was the same animal as that of Experiment 17. About two months and a half after the lesion of the motor region of the right side, the extremity of the left occipital lobe was exposed, and a director passed between the under surface of this lobe and the tentorium cerebelli approximately in the direction of the gyrus hippocampi. A wire cautery was then passed along the groove of the director with the view of destroying the cortex without going through the medullary fibres of the occipital lobe and hippocampal region.

The animal, it will be remembered, was at this time partially hemiplegic on the left side.

After the operation, when consciousness had returned, the conjunctival reflex was distinct on the left, but barely perceptible on the right. Thermal stimulation caused active withdrawal of the left foot, but no movement of the right.

Two hours after the operation the animal was active and vigorous, with the motor powers of the right side unimpaired.

The cremasteric and cutaneous plantar reflexes were distinct on the right side, but not perceptible on the left—the hemiplegic side.

Sensibility was not abolished on the right, but much impaired as compared with the left. Severe thermal stimulation caused reaction on the right, but less marked than on the left. Pinching, pricking, &c., of the left limbs invariably caused signs of uneasiness and struggles to escape, whereas the same on the right caused no sign at all, or only very slight on increasing and prolonging the stimulation. The reaction to the vapour of acetic acid appeared less active in the right nostril than the left. Sight, hearing, and taste seemed quite as acute on the right as left.

Next day the repetition of the tests of tactile sensibility revealed similar signs of impairment on the right; and again on the fifth day. The cutaneous plantar reflex of the right side was better than on the left, yet the right foot might be pinched or pricked without causing such vigorous reaction or signs of sensation as on the left.



On the eighth day the difference, if any, was very doubtful, and examination at various times subsequently did not indicate any perceptible difference as to the signs of sensation on the right and left side to various forms of tactile stimuli. The animal, which continued hemiplegic on the left side, was killed with chloroform considerably over a year after the above-mentioned operation.

Post-mortem examination.—The condition of the right hemisphere has been already described and figured.

In the left hemisphere an orifice, slightly torn, existed at the posterior extremity of the occipital lobe, indicating the point of entrance of the cautery. This led into a shallow groove passing along the upper two-thirds of the gyrus hippocampi (lingual lobule), exactly confined between the calcarine and collateral fissures, and ending at a point one centimetre posterior to the uncus, where the cautery appeared to have entered and buried itself (fig. 103).

The grey matter of the posterior three-fourths of the gyrus hippocampi appeared to have been peeled or shelled off, exposing the medullary fibres and outline of the cornu ammonis. The cortex of the anterior extremity of the gyrus hippocampi and uncus was uninjured superficially.

The base of the brain otherwise—the crura cerebri, optic tracts, and cranial nerves—was intact.

A series of sections, cut obliquely downwards and forwards parallel to the fissure of ROLANDO, of which sun-prints are given in figs. 104–109, showed that the cortex of the gyrus hippocampi had been for the most part sheared off down to the medullary fibres of the cornu ammonis.

This was exposed, but not separated from its medullary connexions, so that it projected in the sections like a crozier. Towards the lower or anterior portion of the gyrus there still remained a portion of the cortex, adjoining the collateral fissure, while that immediately supporting the hippocampus was removed (figs. 106–108).

In the sections which cut the anterior third of this region it was seen that the cautery had penetrated the anterior portion of the hippocampus and nucleus amygdalæ, causing a hole in this region, as seen in transverse section (fig. 109). The convex aspect of the gyrus hippocampi was at this point intact.

Remarks.—This experiment shows that destructive lesion implicating the cortex of the gyrus hippocampi, and perhaps to some extent the medullary fibres of the hippocampus or cornu ammonis, causes some degree of impairment of tactile sensibility, at first well marked, but becoming less distinct, and not perceptible to ordinary tests a week after the operation.

The case was instructive in the comparison (for which the double experiment was devised) which it allowed between the effects of lesion of the motor region and of the hippocampal region. Though the left limbs were greatly impaired as to motor power, no defect could be discovered in their sensibility throughout; while the right limbs

unimpaired as regards their motor power, were for a time markedly defective as regards sensibility.

Notwithstanding the extensive lesion of the hippocampal region, there was no trace of descending degeneration in the opposite side of the spinal cord, though the animal had lived more than a year after the establishment of the lesion in question.

Experiment 25 (Plate 29, figs. 110–116).

In this animal the right occipital lobe was first exposed, and a wire cautery was thrust through the lobe at the anterior extremity of the superior occipital sulcus, in the convex aspect of the lobe, downwards and forwards, with a view to plough along the hippocampus.

While the animal was recovering during the application of the surgical dressings the right pupil was observed to be somewhat smaller than the left. When set free the limbs on the left side were moved and planted with some appearance of uncertainty. An hour and a half after the operation there were signs of defective vision towards the left side, as the animal did not appear to observe threatening gestures made on the left, whereas it made grimaces when the same were made on the right front. Repeated tests were made as to the effects of thermal stimulation on the right and left side respectively, with the result of showing that though signs of sensation could be elicited on the left as well as on the right, they were much less distinct on the left side, whether on the ear, hand, trunk, foot, or tail.

Next day similar observations were made as to the effects of heat, with similar results. As to the perception of mere contact, it was not easy to determine, as the animal was shy and difficult to approach. But as it was still hemiopic towards the left side, advantage was taken of this, and a long wire (cold) stuck in the end of a stick was made to come into contact with the hands and feet from the left, without attracting the animal's sight.

When the fingers or toes of the right side were touched gently, or scratched in this manner, the animal invariably looked and changed its position; but when the same was done on the left there was not the slightest sign of perception, and no change in position was made. This was repeatedly verified.

Next day similar observations were made with similar results, but occasionally there seemed to be less difference than before. But the left side of the tail was pricked with a pin without causing any sign of sensation, whereas the same on the right caused the animal to turn round and scratch the place in a lively manner. The left hemiopia was still apparent.

On the eighth day the animal was seen to run about most actively, never knocking its head on one side or the other against any obstacles in its path. The hemiopic defect previously existing was now very doubtful.

The cremasteric and cutaneous plantar reflexes appeared somewhat more active on the left side than on the right.

On the fifteenth day the reaction to thermal stimulation was still perceptibly less vigorous on the left than on the right, but three weeks after the operation no difference could be perceived, and the hemiopia formerly existing was no longer discoverable by any test.

Four weeks subsequent to the operation on the right hemisphere the left occipital lobe was exposed and a wire cautery pushed through the occipital lobe at the anterior extremity of the first occipital sulcus, downwards and forwards approximately in the direction of the hippocampus.

Half an hour after the operation the animal was able to move about spontaneously, but it tended to slip and fall over on the right side. The reaction to thermal stimulation at this time was most active on the left, but much less on the right, though it was not entirely absent. Next day more thorough examination of the animal revealed a condition of total blindness towards the right, and evidently, also, some impairment towards the left.

Hearing was also impaired, if not abolished on the right, as the animal did not turn its head to scratching sounds, &c., made near its right ear, as it did to sounds made on the left.

No definite conclusions could be arrived at as regards taste or smell, but these senses did not seem to be affected, as the animal smelt at its food in the usual way and seemed to enjoy it.

Tactile sensibility was still markedly defective on the right side. The animal could not be touched anywhere on the left side without its attention being roused, and causing it to put its hand to the spot, but the right hand, foot, and right side of the tail could be touched without the animal seeming to be aware of the fact. Sometimes the difference seemed doubtful when the face was touched.

The right foot frequently slipped off the perch, and sometimes the animal rested with the toes of its right foot doubled up on the plantar surface.

The same condition as to the various senses was again determined by careful examination on the twelfth day after the operation.

On the fourteenth day blindness to the right side continued, but vision to the left was now good.

No difference could now be made out between the acuteness of hearing on the right and left.

Defective perception of mere contact was still evident on the right side, and apparently more so on the foot than elsewhere.

A month after the operation the defective perception of tactile stimuli was still observable on the right foot, but less so than before. The animal still seemed absolutely blind towards the right.

Two months after the operation the animal was still absolutely hemiopic to the right, but otherwise presented no abnormality.

Ophthalmoscopic examination of the eyes four months after the operation did not

reveal any marked abnormality of the discs, but examination six months after the operation discovered signs of atrophy of the outer side of the right disc, which was the only one examined at this time.

My colleague, Professor MCHARDY, reported, on examination of the discs nine months after the operation, and on comparison with those of a normal Monkey, that there was well marked atrophy and pallor of the outer side of both discs.

The right hemiopia continued till the animal's death by chloroform eighteen months after the first operation.

Post-mortem examination.—The dura mater was adherent over each occipital lobe, at a point corresponding to the anterior extremity of the first occipital sulcus. The occipito-temporal region of both hemispheres was also more or less adherent to the dura mater of the middle fossa, more on the left than the right.

When the hemispheres were removed it was found that the cranial nerves were intact, but the right optic nerve was only about half the size of the left—the difference being greatest in the vertical diameter.

The optic tract on the right side was quite normal, and could be followed round the crus to the corpora geniculata freely without any sign of adhesion or injury.

The left optic tract was appreciably thinner and flatter than the right, and on being followed round the crus it was found that the portion proceeding to the corpus geniculatum externum had been sheared off by the cautery. The portion passing to the corpus geniculatum internum was intact, as well as the brachium of the testis. But the anterior brachium and the anterior tubercle of the corpora quadrigemina were distinctly smaller than on the right side. There was no lesion of these parts, however. The cautery had, with the most remarkable precision, just grazed and divided the optic tract at its junction with the corpus geniculatum externum, leaving everything else uninjured.

Right hemisphere.—At the anterior extremity of the first occipital sulcus on the convex aspect of the occipital lobe there was an erosion where the membrane was adherent; and in the centre of this an orifice, the point of entrance of the cautery. The course of this, not visible on the surface otherwise, was indicated by a small rent, a few millimetres in extent, situated at the lower extremity of the inferior or third temporo-sphenoidal convolution, external to the anterior extremity of the gyrus hippocampi. The course, therefore, of the sinus corresponded almost exactly with the collateral fissure.

The exit of the cautery is marked by a X on fig. 110.

Left hemisphere.—On the convexity of the left occipital lobe above the anterior extremity of the first occipital sulcus there was an erosion similar to that on the right, trenching on the posterior limb of the angular gyrus. In the centre of the erosion was a deeper depression, indicating the entrance of the cautery. The direction of the cautery was next indicated externally by a groove in the gyrus hippocampi, internal to the collateral fissure.

At the anterior extremity of this groove the track of the cautery became lost to sight, it having penetrated the lower extremity of the temporo-sphenoidal lobe external to the anterior extremity of the gyrus hippocampi.

At this point there was some adhesion of the cortex to the dura mater, and some damage was done to the brain in separating it.

The brain was hardened in bichromate of ammonia, and owing to too long immersion was so brittle that the sections frequently broke. It was cut parallel to the fissure of ROLANDO, but the plane of section was not quite transverse, sloping more towards the left. This explains the obliquity presented by the sections on Plate 29, figs. 111-116, arranged from before backwards. Owing also to the anti-actinic colour of the sections the prints are rather indistinct in details of structure.

The sections show that on the right side (on the observer's right) the cautery had, after penetrating the medullary fibres of the occipital lobe, struck into the descending cornu of the lateral ventricle. The posterior extremity of the hippocampus was almost detached by division of the medullary fibres (fig. 116). Fig. 115 shows a point where the cautery penetrated the hippocampus. More anteriorly the cautery left the hippocampus itself and emerged gradually, dividing some of the medullary fibres of the hippocampal region.

In figs. 111 and 112 there is some rupture of the fibres of the internal capsule, due to the brittleness of the sections and injury in mounting.

The corpora quadrigemina, crura, pulvinar and optic tract are altogether free from lesion on this side.

In the left hemisphere the lesion is more extensive.

Fig 116 shows the region of the posterior cornu and base of the hippocampus almost entirely broken up. and a similar condition is seen in fig. 115.

Figs. 114 and 113 show where the cautery struck and carried away the optic tract and corpus geniculatum externum, while the corpus geniculatum internum and pulvinar of the optic thalamus are uninjured.

The cornu ammonis in this region has been extensively injured and portions of the gyrus hippocampi have also been destroyed, though the outer half of this gyrus was not originally in the track of lesion, though somewhat incomplete in the sections owing to their having broken off.

Further forwards the cautery penetrated the under surface of the lenticular nucleus and divided the fibres of the external capsule, and so injured the inferior temporo-sphenoidal region that the sections could be with difficulty kept with all the parts in situ. The anterior extremity of the cornu ammonis was considerably injured, though not entirely destroyed. The medullary fibres of the superior temporo-sphenoidal convolution were seen to be ruptured in many of the sections (fig. 112), but in others (fig. 111) they were not, or only partially, divided.

Remarks.—This experiment is recorded as possessing some features of importance,

though the lesions were somewhat complex, and, owing to the condition of the brain, not very easy of exact estimation.

The temporary hemiopia to the left side is readily explicable by the lesions of the cortex and medullary fibres of the occipito-angular region. The very evident impairment of tactile sensibility of the left side—sensibility to mere contact being apparently completely abolished during the first two or three days, and deficiency being still observable for a whole fortnight after the operation—would seem to be in direct relation to the injury of the hippocampus and its medullary fibres, as this was the only lesion beside that of the medullary fibres of the posterior lobe.

The more extensive destruction of the hippocampal region in the left hemisphere was associated with a more prolonged impairment of tactile sensibility on the right side, though from the first this was not abolished. There was also temporary impairment or abolition of hearing on the right, a fact which receives its explanation in the injury inflicted on the medullary fibres of the superior temporo-sphenoidal convolution.

The lesion of the occipito-angular region reinduced for a time the impaired vision towards the left which had resulted from the lesion in the right hemisphere, but which had been recovered from; but the persistent right hemiopia was evidently due, as had been diagnosed during life, to the lesion of the left optic tract.

In consequence of this lesion there was atrophy of the brachium and anterior tubercle of the corpora quadrigemina on the left side, and atrophy of the right optic nerve. This showed itself during life in well-marked atrophy of the outer sector of both optic discs.

The lesion in the left hemisphere implicated a portion of the basal aspect of the lenticular nucleus, but beyond the slight awkwardness of the movements of the left limbs, which might have been due to their defective sensibility, there was no other motor defect.

Experiment 26 (Plate 30, figs. 117–124).

In this animal the left hemisphere was exposed over the region where the middle temporo-sphenoidal convolution becomes continuous with the occipital lobe, the object being to obtain a better guide for directing the cautery along the hippocampal region. The wire cautery was passed through the convexity of the occipital lobe, above the annectent gyrus, downwards and forwards, with a view to break up the hippocampal region. (As to the actual course, see the post-mortem examination.)

The animal, when let loose after the dressing of the wound, began to sprawl about almost immediately, and within a few minutes had climbed up on its usual perch. The limbs were all moved freely, but frequently the right foot slipped or was planted awkwardly. Tested with a heated wire, there was less marked sign of feeling on the right side than on the left, but sensation was evidently not abolished.

An hour after the operation the animal was very active, running about its cage without any sign of weakness of the limbs. Vision seemed impaired towards the right,

but it was not entirely abolished, and the animal did not knock its head against obstacles on the right side. The signs of sensation on the right side were, however, less vigorous than on the left. Hearing was apparently unimpaired on the right, as the animal turned its head equally sharply to sounds made close to its right ear as on the left side.

Beyond the slight defect in tactile sensibility and vision towards the right, there seemed nothing abnormal.

Next day the animal was in excellent health and vigour. No tactile anæsthesia could be discovered; hearing was acute on both sides; and vision, though apparently defective, continued towards the right.

Nothing else worthy of note was observed, and the animal continued well, with perhaps impaired vision towards the right, for three weeks, when the right occipital lobe was exposed posteriorly, and a wire coated with perchloride of iron was pushed through the extremity of the occipital lobe downwards and forwards, approximately along the hippocampal region.

When the animal had regained consciousness, immediately after the surgical dressing, a heated point applied to the left hand and foot caused scarcely any perceptible sign or reaction, whereas when it was afterwards applied to the right the most lively signs of sensation were induced.

Half an hour afterwards this was repeated with precisely the same result; and an hour after the operation a touch with a stick on the right side at once attracted the animal's attention, but no sign of perception was seen when the same stimulus was applied to the left.

Half an hour subsequently, a watch held near the ear caused twitching of the auricle on either side equally, and caused the animal to look round to the right and left accordingly. Hearing was thus seen to be retained on both sides. But the left auricle was touched and rubbed gently with the finger without causing the slightest appearance of consciousness, whereas the slightest touch on the right ear caused the animal to look and move away.

Similar observations were repeated and the same indications of total loss of perception of mere contact were obtained. The reaction to a heated point was not entirely abolished, but the signs of sensation were much less active than on the right.

Next day various tests were applied in respect to tactile sensibility. There still appeared total loss of sensation of mere contact, though painful stimuli were felt to some extent. While the animal was resting quietly, ruffling the hair and tickling the skin with a long stick on the right side invariably caused the animal to scratch the part; but the same stimulus on the left side caused not the slightest sign of perception. When the point, instead of merely ruffling the hair, was pressed deeply, the animal seemed suddenly to be aware of something and moved away. This test was repeatedly performed with precisely the same result. A heated wire excited attention on the left side, but the signs of feeling were much less lively than on the right. Hearing was

evidently acute on both sides. Vision, however, was profoundly impaired on both sides, but no definite determination could be made as to the exact condition on each side.

On the third day on the animal being tested as regards tactile sensibility there was still very perceptible impairment on the left side, though not so great as before. Vision was still defective, but it was not yet clear how much each eye was relatively affected.

There was still less reaction to heat on the left side than on the right. Ammonia held before the nostrils respectively, caused more active reaction on the right side.

On the ninth day the difference as to reaction to tactile stimulation on the two sides was barely perceptible. Vision was still defective, but during the next few days further tests showed that there was absolute hemiopia towards the left, while vision was retained towards the right. The animal readily seized food, &c., offered it on the right, but lost it towards the left.

From this time onward no further change occurred, the animal remaining absolutely blind towards the left. It was killed with chloroform nearly three months after the first operation.

Post-mortem examination.—On removal of the brain it was seen that on cutting the cranial nerves the right optic nerve was considerably smaller than the left.

The under surface of the temporo-sphenoidal lobes was in points adherent to the dura mater in the middle fossæ, corresponding to the lesions of the hemispheres about to be mentioned.

There was no effusion, and the crura cerebri, pons, and other structures at the base were absolutely normal in appearance.

On tracing the optic tracts, which was readily done, there being no adhesion of the pia mater to them, they could be clearly followed to the corpora geniculata. On the right side, close to the lesion in the hemisphere, there was a yellowish look of the corpus geniculatum externum and extremity of the pulvinar; but there was no softening or solution of continuity, and the discoloration was removed with the pia mater, being of the nature of mere imbibition from the adjacent lesion of the hemisphere. The corpora quadrigemina and the anterior brachia were clearly distinct and normal in appearance.

Left hemisphere.—On the convex aspect of the occipital lobe, at the anterior extremity of the first occipital sulcus, there was a deep incision running parallel to the parieto-occipital fissure and extending upwards almost to the longitudinal fissure; the upper extremity running into this fissure. It was seen that the occipital lobe was thus injured to a much greater extent than had been supposed in the first operation. This deep gash in the occipital lobe led downwards and forwards to a sinus which became visible as a round hole in the middle of collateral fissure. From this point a groove extended forwards, following the course of the collateral fissure to its anterior extremity. The gyrus hippocampi was injured at the margin of the collateral fissure where the

cautery emerged from the occipital lobe, but the greater portion remained intact. (See Plate 30, fig. 117.)

Right hemisphere.—The occipital lobe was much injured and broken up at its posterior extremity. This lobe was truncated owing to the complete removal of the posterior extremity, and the cortex was removed in the middle of the lobe as far as the parieto-occipital fissure.

The under aspect of the lobe was completely hollowed out by a sinus which occupied the position of the calcarine fissure and its margins. These were entirely destroyed. Thence downwards and forwards a remarkable appearance was presented. The gyrus hippocampi was completely shelled off the cornu ammonis as far as the region of the uncus, the cornu ammonis with the fascia dentata being thus exposed to view as if by an exquisite dissection. (See fig. 117.)

The internal margin of this, adjoining the optic tract, was absolutely uninjured, and the fimbria of the fornix, and the tænia semicircularis were beautifully displayed on drawing the parts slightly asunder.

In the figure the course of the optic tract to the corpora geniculata and pulvinar has been exposed by tearing off the pia mater and slight separation of the parts from each other.

Sections were made of the brain obliquely downwards and forwards, parallel to the fissure of ROLANDO, of which sun-prints are seen in figs. 118–124. The plane of section was not at right angles to the long axis, but sloped somewhat towards the left, thus causing some obliquity in the sections. The plane of section strikes the convexity of the occipital region and middle of the hippocampal region.

Figs. 118–119 (L), and 120–121 (R) show the appearance presented by the sections which have not yet struck the central ganglia. On the left side the track of the cautery is seen to divide the medullary fibres and cortex of the gyrus hippocampi at the region where it emerged in the collateral fissure; but the hippocampus itself and the gyrus hippocampi internally are intact, as was also seen in the photograph of the brain (fig. 117).

The right occipital lobe in the region of the calcarine fissure is hollowed out, the walls of this fissure being entirely destroyed, and in continuity with this the gyrus hippocampi has been peeled off the cornu ammonis which is free and uninjured;—being attached only by some of the medullary fibres proceeding to it.

In fig. 122, which cuts the region of the corpora quadrigemina and posterior aspect of the optic thalami and the anterior extremity of the hippocampal region, a notch on the left side, external to the gyrus hippocampi, indicates a transverse section of the groove which ploughed along the collateral fissure; and a notch on the under surface of the gyrus hippocampi on the right side indicates the termination of the lesion which peeled off this gyrus from the cornu ammonis.

In figs. 123 and 124 on the left side the groove in the collateral fissure is still seen, but penetrating less deeply into the medullary fibres of the hippocampal region; while

on the right side the extremity of the cornu ammonis and nucleus amygdalæ are seen intact. The central ganglia, crura, and optic tracts are free from lesion throughout.

Remarks.—The lesion of the left hemisphere in this case, apart from that of the occipito-angular region, divided a portion of the medullary fibres of the gyrus hippocampi and cornu ammonis, but the greater portion of these structures was uninjured. Slight and transient impairment of tactile sensibility only resulted. The impairment of vision towards the right would be accounted for by the lesion of the occipito-angular region; so that the transient impairment of tactile sensibility would be in relation with the injury to the medullary fibres of the hippocampal region, as this was the only other portion of the brain which was the seat of lesion. There was no defect as regards hearing; and there was no lesion of the superior temporo-sphenoidal convolution.

On the right side, apart from the lesion of the occipital lobe, the destruction was limited in a most remarkable manner to the gyrus hippocampi, the whole of which, with the exception of the anterior extremity and portion immediately adjoining the collateral fissure, had been removed. The hippocampus itself, and the greater portion at least of its medullary fibres, had escaped injury. With this lesion of the gyrus hippocampi was associated, in evident causal relationship, a very marked impairment of tactile sensibility in all its forms. This, however, gradually diminished until at the end of ten days it ceased to be discoverable.

Hearing was not in the slightest degree impaired by this bilateral cerebral lesion.

The condition as to vision was rather a difficult one to determine as regards each eye. But it was clearly not dependent on any lesion of the optic tracts or nerves. All that could be made out was that vision was not permanently abolished towards the right side, but whether the hemiopia was symmetrical or not was not determined.

The atrophy of the right optic nerve was purely secondary to the destruction of the visual centres of the cortex, and was not due to any direct injury of the optic tract or its connexions with the corpora quadrigemina or corpora geniculata.

The fact that the right optic nerve was specially atrophied showed that the cerebral centres in relation with the right eye had specially suffered; but an exact estimation of the amount of lesion in the cortex and medullary fibres of the occipito-angular region in each hemisphere could not be made.

Experiment 27 (Plate 31, figs. 125–132).

In this case the left hemisphere was exposed in the region of the incisura præ-occipitalis and pli de passage from the middle temporo-sphenoidal convolution to the occipital lobe. With the aid of a director passed between the under surface of this region and the tentorium cerebelli, the third occipital convolution was divided by a horizontal incision, and another incision continuous with this was carried along posterior to the middle temporo-sphenoidal convolution. The portion of brain included between these two incisions, viz. : the inferior occipital, the lower temporo-sphenoidal convolution, and

the hippocampal region, were scooped out; care being taken to avoid going too far inwards and inflicting injury on the optic tract and crus cerebri. The exact extent of the injury inflicted could only be determined however on post-mortem examination.

Within half an hour after the operation the animal was quite on the alert, and was able to sit up, but it rested with the right hand doubled up, and frequently fell over on the right side when it tried to move.

At this time and for the next hour the animal allowed a heated wire to lie in contact with the right hand and foot altogether unheeded, the faintest touch on the left caused the most lively signs of sensation.

The whole of the right side was gently touched and rubbed, or deeply pricked and pinched without the slightest sign of sensation; whereas on the left the animal's attention was invariably excited and directed to the part touched.

Hearing was retained on the right side as acutely, to all appearance, as on the left; the slightest scratching or tapping near the right ear causing the animal to look round, precisely as it did on the left. When the animal had its eyes shut the slightest sound near its right ear caused it to open its eyes and look.

As to vision there was some doubt as to whether this was affected towards the right. To the left it was undoubtedly retained.

The animal sat with the right hand sprawling outwards. While it was so resting, and with its eyes shut, I drew away the right arm until the animal fell over, without its having opened its eyes or shown the least sign of perception. The muscular sense of the right arm was thus shown to be abolished, and the awkward position and doubling up of the right limbs would be similarly accounted for.

Next day the condition of the animal was essentially the same. It planted the right hand and foot in an awkward and abnormal manner and continually tended to fall over on this side. But there was no motor paralysis. It used the right hand and foot for grasping purposes, and when laid hold of it struggled and gripped firmly with all four limbs.

The eyes were open equally, the pupils of moderate size, equal and contractile.

Vision seemed somewhat impaired towards the right, but not abolished, as the animal was able to put out its right hand to lay hold of a chestnut offered it on the right, but it did so with a little uncertainty and want of precision.

Hearing was unimpaired on the right side.

Tactile sensibility was still almost nil on the right side. The animal allowed a degree of heat against any part of its right side without the slightest sign of perception or uneasiness, which immediately caused the most lively manifestations of pain on the left side.

It paid no attention whatever to touching or scratching the right hand or foot with the point of a stick. When this was done on the left the animal invariably tried to lay hold of the stick and push it away or angrily bite it.

The animal being then taken out of the cage and held firmly, a spill of paper

introduced into the right nostril caused little or no sign of uneasiness, whereas on the left the animal made a violent grimace and active endeavour to escape.

The vapour of ammonia in the left nostril caused very active wincing. On the right the reaction was much less marked.

On testing the resistance of the limbs, that of the right seemed much less than on the left, but every movement was carried out on the right as well as left.

The tendency to fall down on the right side was specially seen when the animal dozed. When resting on its perch it frequently slipped on the right, and only succeeded in recovering its balance with the aid of the left limbs.

The animal, which seemed quite well in general health on the second day, was found dead on the third day from some unknown cause.

Post-mortem examination.—The edges of the wound looked rather inflamed, which made it appear as if the antiseptic precautions had not been successful. The signs of inflammation and slight oozing were, however, entirely confined to the tissues of the scalp and edges of the wound.

There was no hernia cerebri, and there was no effusion on the surface of the brain; but on removal of the brain the left middle fossa was found filled with a recent clot which had come from the injured surface of the brain, and which was evidently the cause of death. The effusion did not extend to the base of the brain.

All the cranial nerves were intact and normal, and so also were the pons, medulla oblongata, and cerebellum on its upper and under surface.

On carefully separating the gyrus hippocampi from the optic tract and crus on the left side, the inner margin of the gyrus was found uninjured and not adherent to the optic tract or crus. The optic tract was followed readily to the corpora geniculata, pulvinar and corpora quadrigemina, all of which were uninjured. (See fig. 125.) Along the inner edge of the gyrus hippocampi, the fimbria of the fornix, and the tænia semicircularis were seen intact, and could be followed to the uncus gyri hippocampi, which with the outer root of the olfactory tract was uninjured.

With the exception of a portion of the gyrus hippocampi (lingual lobule) immediately adjoining the calcarine fissure, the whole of the hippocampal region and inferior temporo-sphenoidal region had been destroyed. The lesion trenched on the middle temporo-sphenoidal convolution (fig. 126), but the greater portion of this remained uninjured. The inferior occipital convolution was also carried away.

The lesion might be described as an incision following the line of the second occipital sulcus continued to the extremity of the second temporo-sphenoidal sulcus, extending horizontally inwards and detaching the whole of the occipito-temporal surface of the hemisphere, as far as the hippocampal fissure, and within a short distance of the calcarine fissure.

Frontal sections through the left hemisphere (figs. 127–132), arranged from behind forwards, show that some portions (fig. 127) still remained of the gyrus hippocampi and hippocampus itself in the neighbourhood of the calcarine fissure. In fig. 129,

the region of the pulvinar and corpora geniculata, everything is gone below the middle temporo-sphenoidal convolution, a portion which also is gone. Fig. 130 is a section somewhat further forwards showing essentially the same condition; while figs. 131 and 132, in the region of the lenticular nucleus, show the similar complete removal of the hippocampal and inferior temporo-sphenoidal region, everything else being absolutely intact.

Remarks.—The destruction of the hippocampal region in the manner carried out in this experiment involves many risks and is purely a matter of calculation founded on anatomical measurements of the probable depth of the parts which it is desired to reach, as they cannot be exposed to view.

From an operative point of view the experiment left little to be desired, but unfortunately when all seemed to be going well it was cut short, apparently by secondary hæmorrhage from the injured surface. Hence was lost an opportunity of determining the permanency of the condition of total hemianalgesia and hemianæsthesia so well manifested in this case. In addition to the insensibility to pain and contact, cutaneous and mucous, the condition of the limbs indicated loss of the so-called muscular sense. There was no motor paralysis—every volitional movement being capable of being carried out. But the awkward manner in which the animal planted its limbs, and slipped and fell repeatedly on the right side, especially when its attention was withdrawn, is typical of the condition termed loss of the muscular sense. Hearing was absolutely unimpaired on the right side, and it is seen that there was no lesion of the superior temporo-sphenoidal convolution.

The only abnormality besides loss of tactile and muscular sensibility on the right side was slight impairment of vision towards the right—a condition readily explicable by the lesion of the cortex and medullary fibres of the occipito-angular region.

The total absence of lesion in the crus, central ganglia and internal capsule, and the accurate limitation of the lesion to the hippocampal and lower temporo-sphenoidal region, proves conclusively that in this region are situated the centres of tactile and muscular sensation.

Experiment 28 (Plate 31, figs. 133–140).

In this case, as in Experiment 27, the left hemisphere was exposed in the region of the junction of the temporo-sphenoidal with the occipital lobe, and at this point a horizontal incision was made with a wire cautery guided by a director, and another along the second temporo-sphenoidal fissure with a view to separate and detach the inferior temporo-sphenoidal convolution and hippocampus, as in the last experiment. The operation was effected with little hæmorrhage, and the animal in the course of an hour was able to make efforts to sit up, moving all four limbs, but always falling over on the right side as soon as it gained the upright position.

At this time, and for two hours after the operation, frequent observations showed

that there was no reaction to a heated point placed against the right hand or foot, whereas on the left the signs of sensation were most active.

No determination could be made as to hearing or vision, as the animal would not respond to such tests as were employed. Next day the animal was well and vigorous, and able to run about and climb up the bars of its cage hand over hand. There was no trace of motor paralysis.

Hearing was equally acute right and left, judged by the response to the slightest sound close to each ear respectively. Vision seemed slightly impaired towards the right. The animal seized a piece of carrot offered it on the right, but it seemed to be somewhat uncertain as to the exact position. Tactile sensibility was profoundly impaired, though extreme heat caused withdrawal of the right hand and foot, yet a degree of heat which caused active signs of uneasiness on the left was allowed against the right hand and foot without any sign whatever. Pricking with a pin all over the right side was allowed without any appearance of sensation, whereas on the left the animal invariably winced and struggled to escape. Scratching the right groin and flank with the point of a stick caused no sign of perception, whereas the same on the left caused the animal to twitch its flank as if to shake off a fly in this region. A spill of paper introduced within the right nostril caused barely any sign, whereas on the left an active grimace of uneasiness was caused.

It was observed while quietly eating a piece of carrot which it held in his left hand to accidentally drop the piece, and though it fell in contact with the right hand, the animal did not seem aware of the fact, and groped about with its left hand till it found it.

On the third day the animal appeared in much the same condition, but it did not seem so inclined to run about spontaneously as before. Tactile sensibility was still profoundly impaired on the right side as before.

During the afternoon of this day the animal had an attack of unilateral spasm of the right side, lasting a few seconds, and apparently without loss of consciousness.

Some time after this when the sensibility was again tested, there seemed to be almost complete analgesia over the whole of the right side. Heat which excited lively sensation on the left, caused no indication on the right; and there was no sign of perception of tickling, pricking, &c., on this side.

The right limbs were used now very awkwardly, and occasionally doubled up so that the animal fell over on the right.

On the fourth day this doubling up of the limbs, and planting them in unnatural positions continued, so that the animal continually slipped and fell over on the right. But when it was taken out and examined, it was found that every volitional movement of the limbs was capable of being carried out, and the animal could grip with both hand and foot on the right as well as on the left. Tactile sensibility, as regards touch, tickling, &c, was absolutely abolished on the right side, the same stimulus invariably attracting the animal's attention on the left.



A heated wire seemed not at all perceived on the right foot, and if at all only barely on the right hand. The same stimulation on the left caused active signs of sensation. Tickling of the right nostril with a spill of paper caused no particular sign, whereas on the left the animal resented it much and made grimaces of uneasiness.

It laid hold of food offered it almost exclusively with the left hand. Occasionally it used the right and allowed the things to drop.

These observations were made in the morning of the fourth day. The animal was found dead in the evening.

Post-mortem examination.—On removal of the dressings the edges of the wound were found united except at the anterior extremity. There was no suppuration. On reflection of the integuments, a clot was found projecting from the orifice of the skull, above the left ear. On removal of the brain the left middle fossa was found filled with a quantity of broken-down cerebral substance and recent effusion which had come from the injured temporo-sphenoidal lobe. There was no appearance of inflammation or suppuration either on the convexity or base of the brain, and no effusion except the recent hæmorrhage in the middle fossa.

The cranial nerves were intact, and the cerebellum uninjured. The pia mater stripped readily from the whole surface. The optic tracts, corpora geniculata, corpora quadrigemina and crura cerebri were perfectly normal. The inner margin of the gyrus hippocampi was intact, with the exception of a fissure which ran across it at the lower third (fig. 134).

The left hemisphere in the region of the incisura præ-occipitalis (fig. 133) was somewhat eroded and raised above the surrounding cortex, and from thence in the occipito-temporal aspect of the hemisphere there was an irregular lesion destroying the inferior temporo-sphenoidal convolution, and, as seen superficially, the middle of the gyrus hippocampi across which a crack ran into the hippocampal fissure.

The surface of the region of the uncus seemed intact, and also the region between the calcarine and collateral fissure—the lingual lobule.

Frontal sections of the hemisphere (figs. 135–140), at right angles to the longitudinal axis, showed that the region of the calcarine fissure—the calcar avis—was intact. But opposite the point where the calcarine and hippocampal fissures became continuous with each other (fig. 135) the lesion broke down the external wall of the posterior cornu of the lateral ventricle, and continuing forwards as seen in figs. 136, 137, and 138, entirely detached the inferior temporo-sphenoidal and hippocampal region. Further in advance (fig. 139) portions of the hippocampal region still remained attached, but the medullary fibres were yellowish and softened and nearly severed.

At the extremity of the descending cornu and region of the nucleus amygdalæ the cortex and medullary fibres were uninjured (fig. 140).

Apart from the lesion of the cortex and medullary fibres of the inferior temporo

sphenoidal and hippocampal region there was no other injury ; the optic tracts, crus cerebri and basal ganglia being absolutely intact.

Remarks.—In this case there was some reason for believing that the antiseptic arrangements were defective, and that in consequence the primary lesions had become the centre of secondary inflammatory processes, shown in the unilateral spasms on the third day and subsequent secondary hæmorrhage.

The symptoms of anæsthesia also became intensified. Though at first these were of a most pronounced character, sensibility to mere contact being abolished, but analgesia not complete, on the third day tactile sensibility in all its forms was completely abolished. Though there was no motor paralysis, the manner in which the limbs were used indicated also abolition of the so-called muscular sense.

Hearing was throughout unimpaired, and vision to the right was only slightly impaired, due evidently to the lesion inflicted on the cortex and medullary fibres of the visual centres.

Again the attempt was unsuccessful to maintain the animal alive for any lengthened period of observation. Another similar attempt was made in the following experiment.

Experiment 29 (Plate 32, figs. 141–148).

In this case the left hemisphere was exposed as in the two previous experiments over the region of the incisura præ-occipitalis, and the hemisphere incised with the cautery horizontally underneath the inferior occipital convolution, and also along the posterior border of the middle temporo-sphenoidal convolution ; the portion between the two incisions being disorganised as much as possible without injuring the crus, so far as could be judged.

The animal an hour and a half after the operation was able to sit up, using all four limbs freely, but always fell over on the right side, the limbs on this side seeming suddenly to give way. At this time the slightest scratching or sound made near the right ear caused the animal to open its eyes and look round to this side.

Tactile sensibility, tested with heat, was profoundly impaired, there being scarcely any reaction on the right side to a degree of heat which caused the most lively signs of feeling on the left—on the face, hand and foot.

Next day the animal was in excellent health and vigour. Hearing and vision to the right side were unimpaired. It turned sharply to the slightest sound near the right ear, and picked up food, and took things held to its right side. Tested with heated point there was some reaction to severe stimulation on the right, but much less than on the left. While the animal was holding by the bars of the cage with both hands, a heated wire applied to the right hand caused no movement, but placed directly after—and so much cooler—on the left hand caused the animal to withdraw this hand sharply and rub it vigorously.

Similarly as regards pricking the hands with a pin. A spill of paper introduced into

the left nostril caused active retraction of the head and a snort or sneeze, whereas on the right very little movement was excited.

The animal, which appeared quite strong on the evening of the second day, was found dead on the morning of the third day.

Post-mortem examination.—On removal of the dressings it was found that a recent hæmorrhage had occurred filling the left middle fossa, and extending from this to some extent over the convexity of both frontal lobes.

On removal of the brain it was found that the cerebellum, pons, medulla oblongata and all the cranial nerves were uninjured. The crura cerebri and corpora quadrigemina were intact. The optic tracts were uninjured, and readily traceable to the corpora geniculata.

The brain was everywhere uninjured except in the left occipito-temporal region. The inferior temporo-sphenoidal convolution and anterior portion of the inferior occipital convolution had been disorganised by an irregular section which extended across the collateral fissure into the outer half of the gyrus hippocampi. The surface of the section was ragged and the whole of the inferior temporo-sphenoidal, and outer half of the gyrus hippocampi thoroughly disorganised. The inner half of the gyrus hippocampi was quite free from lesion, and of a normal aspect on the surface (fig. 141).

The lingual lobule was intact.

Frontal sections of the left hemisphere (Plate 32, figs. 143–148) arranged from before backwards, showed that in the region of the nucleus amygdalæ (fig. 143) there was a superficial lesion of the gyrus hippocampi adjoining the extremity of the collateral fissure, penetrating more deeply and dividing the medullary fibres slightly posterior to this (fig. 144). Further back (figs. 145 and 146) the lesion had destroyed the cortex of the outer half of the gyrus hippocampi, and completely severed the medullary fibres of the cornu ammonis, which itself was intact. Still farther back (fig. 147) the cortex of the gyrus hippocampi was entirely removed externally, and also the cortex of the inferior temporo-sphenoidal region. The cornu ammonis still remained connected with the finbria. At the junction of the posterior and inferior cornua (fig. 148) the lesion gradually came to an end with destruction of the cortex on each side of the collateral fissure, and partial lesion of the medullary fibres of the base of the cornu ammonis.

Remarks.—This case, like the two former, was again unsuccessful so far as related to the opportunities of continued observation. But it again demonstrates the important fact that destructive lesions implicating only the inferior temporo-sphenoidal and hippocampal region cause profound impairment of tactile sensibility, in all its forms, without any motor paralysis whatever.

In this case also there was no appreciable impairment of vision due to the comparatively slight, if any, injury to the occipito-angular region. Hearing also was unimpaired, and as before, the superior temporo-sphenoidal convolution was entirely free from lesion.

Experiment 30 (Plate 33, figs. 149-156).

In this case the right hemisphere was exposed over the incisura præ-occipitalis, and an incision was made with the cautery along the posterior border of the middle temporo-sphenoidal convolution, and another from the upper extremity of this incision horizontally inwards below and parallel to the second occipital sulcus, the parts between the two incisions, viz., the inferior temporo-sphenoidal convolution and hippocampal region, being considerably broken up.

An hour after the operation the animal was able to sit up and use all its limbs, though the left seemed awkward. It could use its left hand to pick up pieces of food, but occasionally let them drop. Sight to the left was retained, as the animal put out its left hand to lay hold of, and push away a stick made to approach its left side. It was also seen to pick up a piece of potato lying to its left side. Hearing on the left side was undoubted, the slightest scratching or similar sound near the left ear causing the animal to turn sharply round and look.

Tactile sensibility was much impaired, but not entirely abolished, on the left side. Heat caused much less indication of painful sensation on the left as compared with the right.

Next day the animal was in good health and vigour.

Sight and hearing were equally acute on both sides. There was no motor paralysis. Tactile sensibility was still impaired. The fingers of the left hand could be touched gently, or rubbed, without attracting the animal's attention; whereas the same on the right caused the animal to look or move away from its position. The reaction to heat was less active than on the right side—determined by the grimaces and movements of the animal.

On the fourteenth day it was impossible to determine any difference as regards the tactile sensibility on the two sides. The animal seemed in perfect health. On this day the left occipital lobe was exposed posteriorly, and a wire cautery pushed through it downwards and forwards, approximately in the course of the hippocampal region.

An hour after the operation, while the animal was sitting up, but leaning towards the right, thermal stimulation of the left and right side respectively showed that, though severe stimulation caused signs of feeling on the right, yet a degree of heat which excited lively signs of feeling on the left was allowed in contact with the right hand and foot without causing any movement or sign of uneasiness.

There was total insensibility to mere contact. The right hand and foot could be touched or gently rubbed without any sign of perception on the part of the animal; whereas the same on the left caused the animal to look and move away from the disturbance.

There was no motor paralysis. All the limbs were freely moved. But the animal for purposes of prehension used the left hand almost exclusively. Hearing to the right was undoubtedly retained. Further observations an hour later showed that vision

was unaffected towards the right side. The animal was seen to pick up a piece of apple lying to its right side. It was also able to crawl through an opening into the next cage without knocking its head on one side or the other.

Next day the animal was found in a comatose condition, and was chloroformed to death.

Post-mortem examination.—The dura mater stripped readily over the whole convexity of the brain, which was quite free from signs of inflammation or effusion; and, with the exception of lesions to be described, the rest of the brain, with the cranial nerves, had a perfectly normal appearance.

In the *right* hemisphere the posterior half of the middle temporo-sphenoidal, and the whole of the inferior temporo-sphenoidal convolution had been sheared off close up to the collateral fissure, the lesion extending slightly across it at the middle. But the gyrus hippocampi was on the surface almost wholly intact.

On the *left* side in the middle of the convex aspect of the occipital lobe posteriorly there was a hole, the entrance of the cautery. This had penetrated the lobe downwards and forwards and emerged in the line of the collateral fissure, cutting a deep groove here on the occipito-temporal surface of the hemisphere. At the lower extremity of the collateral fissure the cautery had again buried itself, and emerged at an irregularly-shaped orifice, situated at the inferior extremity of the third temporo-sphenoidal convolution external to the tip of the gyrus hippocampi.

The course of the cautery would be indicated by a straight line following the direction of the collateral fissure from the occipital lobe to the anterior extremity of the temporo-sphenoidal lobe.

Frontal sections of the brain arranged from behind forwards (Plate 33, figs. 150–156) show that in the *right* hemisphere (to the right hand) the lesion commenced near the junction of the posterior and descending cornu of the lateral ventricle, destroying the cortex of the inferior and posterior half or two-thirds of the middle temporo-sphenoidal convolutions, and extending so far inwards as in parts entirely to sever the medullary connexions of the hippocampal region, and in others so far as to render it impossible to mount the sections with all the parts *in situ*.

The anterior third of the gyrus hippocampi and cornu ammonis were entirely free from lesion.

In the *left* hemisphere it is seen that the course of the cautery was through the posterior cornu, destroying the cornu ammonis and the medullary fibres of the gyrus hippocampi as well as those passing to the inferior and middle temporo-sphenoidal convolutions. The cortex of the gyrus hippocampi formed a thin shell, enclosing broken-down débris.

The anterior sections (figs. 155 and 156) show that the course of the cautery passed just external to the cornu ammonis itself, severing the gyrus hippocampi and its medullary fibres, and also fissuring and detaching the inferior and middle temporo-sphenoidal

region, as well as implicating to a slight extent the superior temporo-sphenoidal where it borders on the first temporo-sphenoidal fissure.

The crura cerebri, internal capsule, and central ganglia are seen to be free from lesion in both hemispheres.

Remarks.—This case shows that destruction of the whole of the inferior temporo-sphenoidal, and portion of the middle temporo-sphenoidal convolutions, with considerable destruction of the medullary fibres passing to the gyrus hippocampi and cornu ammonis, only partially impaired tactile sensibility on the opposite side.

At first the impairment was very distinct, and amounted almost to analgesia, but this gradually gave way and ultimately entirely disappeared, so that within a fortnight it was not possible to discover any difference in the reactions of the two sides. Sight and hearing were unimpaired from the first, and there was no motor paralysis.

The subsequent destruction of the hippocampal, and medullary fibres of the inferior temporo-sphenoidal region on the left, induced almost absolute analgesia as well as complete insensibility to mere contact on the right side; motor power, vision, and hearing being clearly retained.

Unfortunately the permanency of the symptoms could not be determined owing to the death of the animal very shortly after the establishment of this lesion.

Experiment 31 (Plate 34, figs. 157–163).

In this animal the left hemisphere was exposed in the region of the incisura præ-occipitalis, and two incisions made with the cautery, one along the posterior border of the middle temporo-sphenoidal convolution, and another horizontally inwards from the upper extremity of this incision so as to divide the upper or posterior portion of the gyrus hippocampi from the rest. The portion of brain included between these two incisions was disorganised by the cautery, and the surface touched with perchloride of iron to arrest hæmorrhage.

An hour after the operation the animal, which had quite recovered consciousness, was very unsteady when it tried to move about, falling down on the right side.

Heat applied to any part of the right side caused barely any sign of reaction, whereas on the left the most lively signs of sensation were evoked.

Some time subsequently while the animal was being held numerous tests were made as to tactile sensibility. Pricking and pinching the fingers and toes of the right side caused very slight if any indications of sensation, but on the left the same caused the animal to exhibit signs of uneasiness, rub the part, and struggle to get away. Tickling the interior of the right nostril caused no reaction, on the left the same caused the animal to rub its nostril with its hand and make a grinace. The animal's tongue protruded at the tip and the right side could be touched and pricked gently with the point of a pin without causing any reaction, whereas on the left the same caused the animal to rub at the part.

Within two hours after the operation clear evidence was obtained of retention of hearing in the right ear. While it was sitting dozing, a slight whisper made near its right ear caused it to open its eyes and look round. No further observations were made this day, and next day the animal died suddenly before any further observations could be made.

Post-mortem examination.—On removal of the dressings there were signs of recent hæmorrhagic extravasation at the orifice in the skull. On removal of the brain the left middle fossa was found filled with recent clot, some also having made its way to the anterior surface of the pons and medulla.

There was no injury to the cranial nerves, crura, or cerebellum. On examination of the left hemisphere it was found that the posterior half of the middle temporo-sphenoidal convolution, the whole of the inferior temporo-sphenoidal convolution, and the gyrus hippocampi, except the inner margin, were broken up and destroyed. The region of the uncus was intact. The cornu ammonis itself, however, was still traceable among the débris at the bottom of the wound, and careful separation of the parts showed the fascia dentata, corpus fimbriatum, optic tracts, corpora geniculata, and corpora quadrigemina perfectly intact. This is well displayed in Plate 34, fig. 157, where all these parts have been exposed to view by merely pushing the hemispheres upwards and forwards, and drawing them asunder.

Microscopical examination.—Frontal sections of the left hemisphere (Plate 34, figs. 158–163) showed that the occipito-temporal regions were so disorganised that they fell away from the rest on being cut, carrying the cornu ammonis and fimbria with them. At the anterior third of the gyrus hippocampi the lesion (fig. 162) did not entirely detach the gyrus hippocampi, and in the region of the nucleus amygdalæ (fig. 163) a small hole indicates the termination of the lesion.

Remarks.—In this case, in which again fatal secondary hæmorrhage cut short the observations, the disorganisation of the inferior temporo-sphenoidal and hippocampal region was marked by the most profound anæsthesia of the opposite side of the body, both on the cutaneous and mucous surfaces. All the volitional movements were retained, but the manner in which the animal tended to fall over on the right side indicated the loss of the so-called muscular sense.

Experiment 32 (Plate 35, figs. 164–172).

In this case the posterior extremity of the left occipital lobe was exposed, and a director inserted between the under surface of this lobe and the tentorium cerebelli approximately in the direction of the gyrus hippocampi. A heated wire was then passed along the groove with the view of destroying this region.

The animal soon recovered consciousness and began to make spontaneous movements. To various forms of stimuli, heat, &c., there was distinct reaction from the first, and further careful and repeated observations showed a remarkable degree of hyperæsthesia

over the whole of the right side. The demonstrations of sensation to heat, pinching, pricking, &c., were much more lively on the right side than on the left, and the sensation caused by plucking the hairs on the right hand was, judging from the animal's gestures, much more acute on the right side.

Gentle sounds near the right ear caused the animal to turn and look exactly as on the left. The condition as to vision was not determined this day.

Next day the animal was able to run about actively and climb as usual. Hearing was evidently equally acute on both sides, but there seemed some impairment of vision towards the right. No difference could be detected as regards smell in the two nostrils. When a fine wire dipped in oil of bergamot was held to each nostril—the other being closed—the animal sniffed equally as if smelling. (This odour seems very agreeable to Monkeys, as they always sniff it as if enjoying it.)

As to tactile sensibility no difference could be made out between the two sides. The hyperæsthesia of the day before had disappeared.

On the seventh day there still seemed slight uncertainty as to the exact position of things on the extreme right, but the animal was able to pick up things lying on the floor of the cage to the right as well as to the left side.

On the tenth day the animal seemed perfectly normal in respect to all its faculties and powers.

Four weeks subsequently to the first operation the right hemisphere was exposed over the region of the incisura præ-occipitalis, and by means of a cautery, guided by a director, the temporo-sphenoidal lobe was incised along the middle temporo-sphenoidal convolution and also horizontally inwards towards the gyrus hippocampi. The portion of brain between the two incisions was left *in situ*, with a view to prevent the risk of secondary hæmorrhage, which had previously proved so fatal.

Within half an hour after the operation the animal was able to sit up, but unsteadily, the left limbs being planted awkwardly, and tending to double up.

Tactile sensibility at this time was greatly impaired all over the left side. The animal allowed a degree of heat which excited the most lively demonstration, and rubbing of the part touched, on the right side, to be applied to the left side of the tail, trunk, hand, and foot without making any sign of uneasiness.

So also pricking, gently tickling and ruffling of the hair on the left side caused no sign of perception, whereas on the right the animal invariably put its head or foot to the part, and in so doing fell over on the left side.

Tickling of the right nostril caused evident sign of uneasiness; of the left no perceptible sign.

The condition as to hearing and vision on the left was not determined. Hearing was undoubted towards the right however.

Next day vision was seen to be unimpaired to both sides, the animal picking up minute objects to either side equally well. Hearing also was retained in the left ear—the animal turning to sounds on the left exactly as on the right.

As to tactile sensibility there seemed improvement as regards analgesia, but the left side could still be touched, tickled, &c., without exciting attention. On the right side the animal invariably put its hand to the place.

On the third day the difference between the two sides as regards tactile sensibility was less pronounced. In all other respects the animal was perfectly well.

On the sixth day no difference could be made out between the two sides in respect to tactile sensibility. The animal continued from this time in perfect health, and was killed with chloroform a month subsequently—or two months after the first operation.

Post-mortem examination.—The cranial openings were covered by membrane adherent to the subjacent cortex, but elsewhere the whole surface of the brain was free from adhesions.

Except for the lesions about to be described all the rest of the brain was perfectly normal.

At the posterior extremity of the *left* occipital lobe there was a ragged sinus or channel marking the point where the cautery had been introduced. This pierced the tip of the occipital lobe and then immediately emerged, grooving the surface of the gyrus hippocampi (lingual lobule) between the calcarine and collateral fissures. The cautery then ran along the margin of the hippocampal or dentate fissure and plunged ultimately into the nucleus amygdalæ or tip of the gyrus hippocampi. The optic tract though so near the course of the cautery was in a most remarkable manner absolutely untouched, and was freely separable and traceable to the corpora geniculata which were altogether free from lesion.

In the *right* hemisphere there was a deep incision occupying the position of the first temporo-sphenoidal sulcus in its lower half; and from the upper extremity of this, on a level with the anterior extremity of the inferior occipital convolution, there was another deep incision at right angles to the axis of the temporo-sphenoidal lobe, extending exactly to the collateral fissure. The portion of brain included between these two incisions remained *in situ*.

The whole superficial aspect of the gyrus hippocampi was quite intact (fig. 164).

Sections of the brain, parallel to the fissure of ROLANDO (Plate 35, figs. 165–172), show that in the left hemisphere the internal margin of the gyrus hippocampi, at the junction of the posterior and descending cornu of the lateral ventricle (figs. 165 and 167), is grazed. Figs. 169 and 170 show that the fascia dentata has been sheared off. In fig. 171 a portion of the alveus of the cornu ammonis has been carried away, and in fig. 172 a perforation of the nucleus amygdalæ indicates where the cautery left the hippocampal fissure and plunged into the extremity of the gyrus hippocampi.

The lesion is entirely confined to the fascia dentata and alveus of the cornu ammonis, without in any way injuring the medullary fibres of this or of the gyrus hippocampi itself.

In the *right* hemisphere the gyrus hippocampi and cornu ammonis and the medullary fibres passing to this region are seen to be uninjured posteriorly (figs. 166, 168, 169).

In the region of the middle of the collateral fissure, the transverse incision, before described (cut obliquely), extended so far inwards as partially to sever the medullary fibres of the hippocampal region (figs. 170, 171), the cornu itself and the cortex of the gyrus hippocampi being free from lesion. Towards the extremity of the descending cornu the breaking up and detachment of the gyrus hippocampi and cornu ammonis was more complete, the whole of the anterior extremity of the temporo-sphenoidal lobe being more or less broken up (fig. 172).

The central ganglia, internal capsule, optic tracts, and crura were altogether intact.

Remarks.—This case is in some respects very extraordinary, and particularly with reference to the lesion of the left hemisphere. It would seem practically impossible to limit an experimental lesion so precisely to the fascia dentata and alveus of the cornu ammonis, as occurred in this case, without causing injury to other structures—the optic tract or crus cerebri. But no such injury was present. The case is also altogether unique in the symptoms which were induced. Instead of temporary annihilation, or impairment of tactile sensibility, there was for a time well-marked exaltation of sensibility on the opposite side of the body. The lesion, therefore, instead of destroying the centres of tactile sensation, seems to have thrown them into a state of hyperactivity. It may be supposed that the slight destructive lesion of the hippocampal region was accompanied by active congestion of the uninjured portions.

In the right hemisphere the lesion of the hippocampal region was only partial, being confined to the anterior half, and consisting mainly in division of the medullary fibres passing to the gyrus hippocampi and cornu ammonis. The anterior half of the middle and inferior temporo-sphenoidal convolutions were, however, much broken up and disorganised.

The affection of tactile sensibility, at first well marked, ceased to be perceptible after a few days, and apparent complete recovery took place.

With the exception of slight impairment of vision to the right side of a temporary character, due to the lesion of the left occipital region, no other sensory or motor defect, beyond the affections of tactile sensibility above described, appeared to result from the bilateral lesion in this case.

Experiment 33 (Plate 36, figs. 173–181).

In this case the extremity of the left occipital lobe was exposed, and a director passed between the under surface and the tentorium cerebelli downwards and forwards in the direction of the gyrus hippocampi. A wire cautery was pushed along the groove, and afterwards a *porte caustique* tipped with nitrate of silver.

Within an hour after the operation the animal was able to get up and move about, but the limbs of the right side were used awkwardly and planted abnormally.

At this time, though severe thermal stimulation caused some sign of sensation on the right side, the reaction was much less marked than on the left, and a degree of

heat which caused lively signs of pain on the left side evoked scarcely any indication of perception on the right.

Tickling the interior of the left nostril caused a grimace and a snort, but the same on the right very slight, if any, effect.

An hour later the animal, in walking, which it did more freely, frequently fell over on the right side owing to the awkward way in which the right limbs were planted.

There was no motor paralysis of the right limbs however, and the animal was able to grip with the right hand and raise the right arm to the head.

Tickling the left nostril invariably caused the animal to raise its hand and rub the part, but no notice was taken of the same thing on the right.

Next day the animal was seen to run about without any tendency to fall over on the right side, and the right limbs were used in a perfectly normal manner.

Tactile sensibility was in great measure restored, there being only defective sense of mere contact on the right side, but no longer any distinct analgesia. Hearing was undoubtedly retained in the right ear, but there was total loss of vision to the right side. The animal at once seized a piece of food as soon as it crossed the middle line when moved from right to left in front of it.

On the fourth day, except for the right hemiopia, nothing abnormal could be detected.

The animal continued, except for the right hemiopia, which was absolute, in perfect health, and at the end of a fortnight the *right* hemisphere was exposed over the region of the incisura præ-occipitalis.

At the anterior extremity of the inferior occipital convolution, where it joins the middle temporo-sphenoidal, a wire cautery was run along the middle temporo-sphenoidal convolution downwards and forwards to its extremity, and at right angles to this incision, another was carried inwards with a view to divide and detach the inferior temporo-sphenoidal and hippocampal region from the rest of the hemisphere. The parts were not removed, but along the bottom of the incisions a *porte caustique* tipped with nitrate of silver was rubbed, with a view to excite destructive inflammation and adhesion, and so obviate hæmorrhage.

The animal had for a short time after the operation some twitching of the limbs, particularly of the left side.

Within two hours after the operation the animal was quite recovered, and was wide awake; but in trying to sit up or move always fell over on the left side.

At this time a heated point caused barely any sign of reaction on the left side, whereas the same on the right caused very distinct signs of sensation and attempts to rub the part with the hand.

No further observations were made on that day, and next morning the animal was found quite recently dead.

Post-mortem examination.—On examination of the brain there was no sign of inflammation or recent hæmorrhagic effusion.

In the *left* hemisphere, at the posterior extremity of the inferior occipital sulcus, there was a sinus, the entrance of the cautery which became visible superficially immediately external to the posterior extremity of the calcarine fissure, and then became lost to view. The under surface of the occipital lobe was somewhat blackened by the caustic. The course of the cautery remained concealed as far as the inner aspect of the uncus gyri hippocampi, where a small orifice was seen. Here the cautery emerged and grazed the optic tract, which was almost completely severed half way between the chiasma and the corpora geniculata. The crus cerebri was quite free from lesion. The right optic nerve was in sectional area only half the size of the left. In the *right* hemisphere there was an incision from the lower border of the inferior occipital convolution along the first or superior temporo-sphenoidal sulcus, and another at right angles to this, extending inwards to near the inner margin of the gyrus hippocampi. By these two incisions the greater portion of the middle and inferior temporo-sphenoidal convolutions with the hippocampal region were separated from the rest of the hemisphere, but remained *in situ* (fig. 173).

The crura cerebri, corpora quadrigemina, corpora geniculata, and rest of the brain with the cranial nerves were uninjured.

Sections of the brain, parallel to the fissure of ROLANDO (Plate 36, figs. 174–181), showed that in the left hemisphere the cautery had with the utmost precision penetrated the centre of the cornu ammonis and broken it up from end to end without destroying the medullary fibres or cortex of the gyrus hippocampi. In many of the sections the cornu ammonis was merely a mass of blackened débris which fell out on handling. The left optic tract (figs. 178, 179, 180) is seen to have been severed between the chiasma and the corpora geniculata.

In the right hemisphere the sections show an extensive breaking up of the middle and inferior temporo-sphenoidal convolutions, and an almost complete severance of the medullary fibres of the hippocampal region, the destruction being most complete near the anterior extremity of the temporo-sphenoidal lobe, where only a small portion of the inner aspect of the tip of the gyrus hippocampi remained intact. The central ganglia and crura cerebri were uninjured throughout.

Remarks.—In this case the lesion in the left hemisphere was limited with unusual precision to the cornu ammonis itself, which was thoroughly disorganised, without lesion of the medullary fibres or of the gyrus hippocampi. Tactile anæsthesia occurred on the opposite side of the body, both cutaneous and mucous, and the condition of the limbs was indicative of loss of the so-called muscular sense. The symptoms were, however, not of long duration, and already on the fourth day they were no longer discoverable. The right hemiopia proved, as had been diagnosed during life, to be due to lesion of the left optic tract.

Apart from the right hemiopia, there was no other perceptible symptom beyond the loss of sensibility on the opposite side.

The subsequent lesion of the right hemisphere, in which, along with the middle and

inferior temporo-sphenoidal convolutions, the hippocampal region was in great measure detached and destroyed, induced the most profound anæsthesia of the left side. But here again, as in many previous experiments of a similar nature, the animal speedily succumbed, so that further observations with regard to the permanency of the symptoms were rendered impossible.

General Results.

The experiments recorded in this section show that by destructive lesions confined to the cortex and medullary fibres of the inferior and internal aspect of the temporo-sphenoidal lobe, without implication of the crus cerebri, basal ganglia or internal capsule, it is possible to cause complete anæsthesia (cutaneous, muscular, and mucous) of the opposite side of the body, without paralysis of voluntary motion.

In the operations necessary for the establishment of such lesions a certain amount of injury of other regions is unavoidable, but an analysis of the experiments, varied as to the method of performance and the extent to which other regions were involved, shows that the only point in common to all the cases in which there was impairment or abolition of tactile sensibility, was destruction of the cortex and medullary fibres of the hippocampal region; and the degree of impairment of tactile sensibility was in proportion to the extent to which this region was involved.

In my former experiments (*Philosophical Transactions*, Vol. 165, Part 2) I had observed that in several cases of lesion of the temporal lobe, tactile anæsthesia supervened when in the process of secondary softening the hippocampal region became implicated. In Experiments XVII. and XVIII. lesions were purposely primarily established in this region. In Experiment XVII. anæsthesia was not observed till the third day:—the track of the cautery, as was proved post-mortem, having swerved away from the hippocampal region. But as softening invaded the hippocampal region anæsthesia became established. The sections of the hemisphere (figs. 89–94) show that the lesions were confined to the cortex and medullary fibres of the hippocampal and inferior temporo-sphenoidal region.

In Experiment XVIII. anæsthesia followed the lesion immediately, and the animal was killed before any secondary changes could be developed. The sections of the hemisphere show that the lesion was strictly confined to the hippocampal and lower temporo-sphenoidal region (figs. 97–102).

In reference to lesions of the temporal lobe not specially invading the hippocampal region, Experiment 14 is of importance. In this case the region of the middle and inferior temporo-sphenoidal convolutions was disorganised without any indications of tactile anæsthesia. Some extension of the primary lesion occurred secondarily, but whether any anæsthesia resulted was not observed. The fact of importance is that the primary lesions were without discoverable effect on tactile sensibility.

In Experiment 26 also, though the lower temporo-sphenoidal region was destroyed,

and the hippocampal region only partially involved, there was only slight and transitory impairment of tactile sensibility on the opposite side.

These, as well as other similar facts narrated, serve to show that the lesions of the lower temporo-sphenoidal region which are necessarily made in attempts to destroy the hippocampal region from the external aspect of the temporal lobe are negative or unimportant in the causation of the anæsthesia.

Where the hippocampal region was reached through or from the under surface of the occipital lobe, and particularly in the former case, where the medullary fibres of the whole of the posterior lobe were invaded, tactile anæsthesia was complicated with visual defects more or less pronounced. But the experiments recorded in Section I. enable us to eliminate the visual defects and assign them to the lesions inflicted on the occipito-angular region.

The sense of hearing was very rarely affected, and then only when the lesions invaded the medullary fibres of the superior temporo-sphenoidal convolution.

By thus eliminating the effects of lesions of the occipito-angular region, of the superior temporo-sphenoidal, and in large measure at least of the middle and lower temporo-sphenoidal region, we arrive at the lesion of the hippocampal region as the essential factor in the causation of the anæsthesia observed in the various cases.

When the hippocampal region was entirely destroyed, as in Experiment 27, the most complete anæsthesia was manifested on the opposite side, and the degree of anæsthesia varied in other experiments with the completeness of the destruction of this region.

In some of the experiments the apparently impossible feat was accomplished of restricting the lesion to the gyrus hippocampi and hippocampus itself respectively.

When the cortex of the gyrus hippocampi was alone or mainly injured, as in Experiments 24 and 26, there was well-marked impairment of tactile sensibility on the opposite side, but not of permanent duration.

When the fascia dentata and internal margin of the gyrus hippocampi were alone injured, as in Experiment 32, there was a remarkable hyperæsthesia of a transient character, which has already been commented on. In another sense this fact is of importance as showing that the anæsthesia resulting from lesions of the hippocampal region cannot be explained away on any theory of mere proximity of the lesions to the sensory tracts of the hemisphere. For in this case the lesion was nearer the crus cerebri than in any of the others.

When the cornu ammonis alone was the seat of lesion, as in the left hemisphere of Experiment 33, there was for a time very marked anæsthesia of the opposite side. But here, also, as in the cases where the gyrus hippocampi alone was injured, the symptoms were only of temporary duration.

These facts, therefore, show that the hippocampus and hippocampal gyrus form parts of the same centre, and that complete destruction of both structures is necessary to secure complete and permanent anæsthesia. But to effect this primarily is both

difficult and fraught with great risks, either of injury to the crus cerebri or of secondary hæmorrhage, and I have, unfortunately, not succeeded in maintaining any animal, in which this lesion was successfully established, sufficiently long alive to determine the questions that arise with respect to permanency or compensatory action. In Experiment 25 the greatest amount of damage was inflicted with long survival, but the anæsthesia in this case was only partial from the beginning, and the lesion did not destroy the whole of the hippocampal region.

It is comparatively easy to secure total destruction of the hippocampal and lower temporo-sphenoidal region by operations conducted without antiseptic precautions, as the primary lesions become the centres of secondary inflammatory processes. In all cases where this occurred the anæsthesia, at first partial, deepened and became absolute. But this condition is incompatible with long survival or accurate determination of the extent of the primary lesion.

In addition to the positive evidence furnished by these experiments in favour of the localisation of the centres of tactile sensibility in the hippocampal region, I would also adduce the negative effect as regards tactile sensibility of all the other cerebral lesions here recorded, involving the occipital, parietal, and frontal lobes. In none of these, however extensive, was any impairment of tactile sensibility observed, even of the most transient duration.



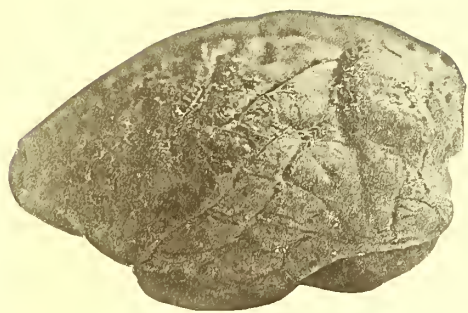

Fig. 1

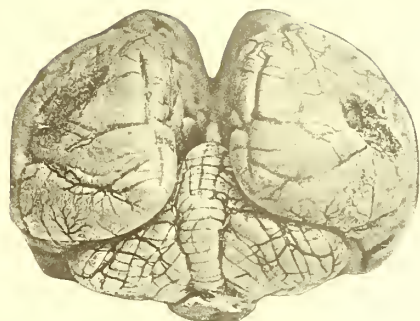

Fig. 2

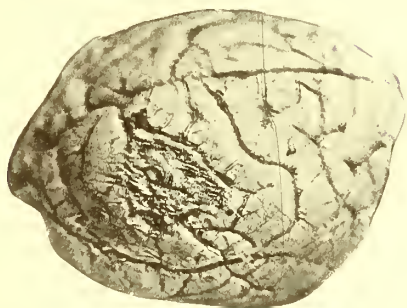

Fig. 4



Fig. 3

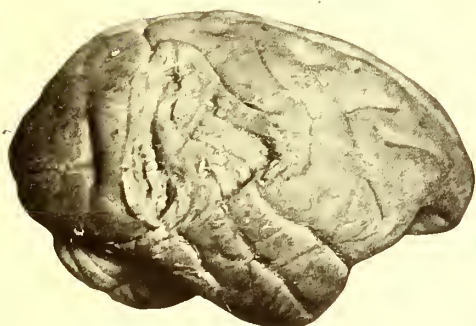

Fig. 5

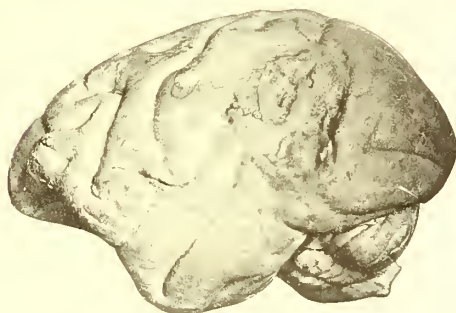


Fig. 6



Fig. 8



Fig. 7

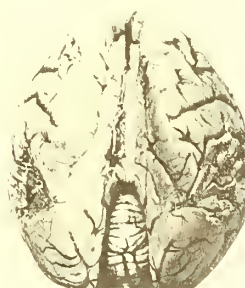

Fig. 9

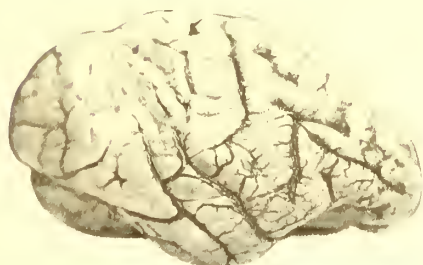

Fig. 10

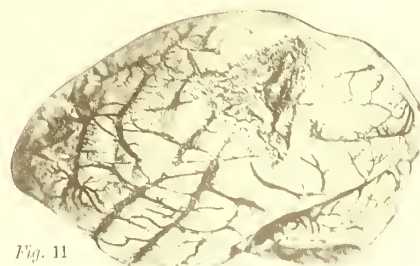


Fig. 11

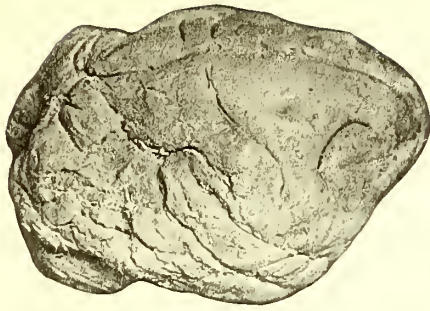


Fig. 12

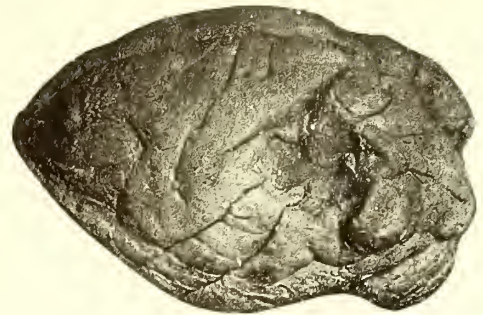

Fig. 13

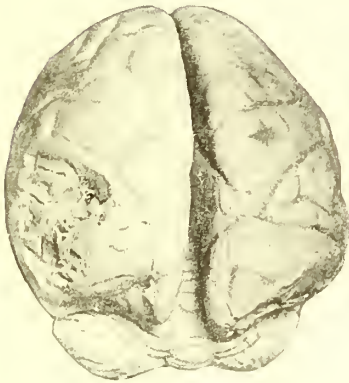

Fig. 15



Fig. 14

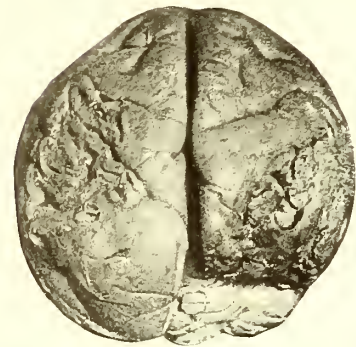

Fig. 16

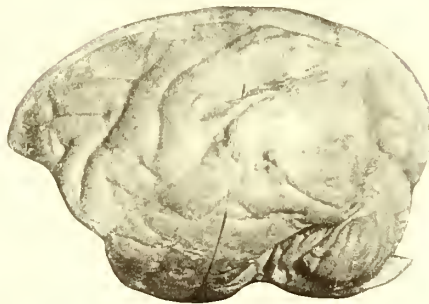


Fig. 17

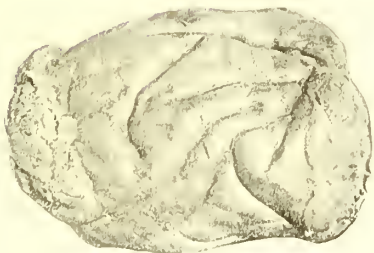


Fig. 18

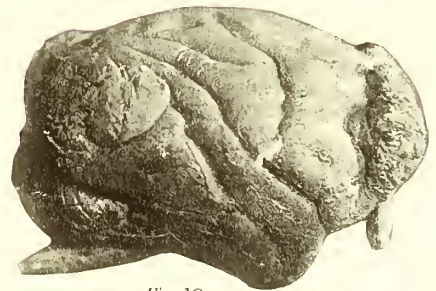

Fig. 19

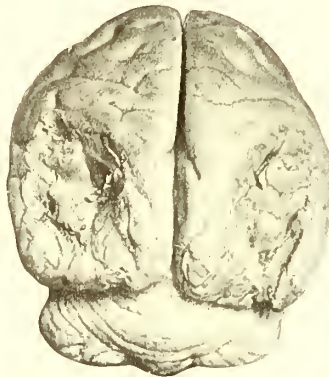


Fig. 20

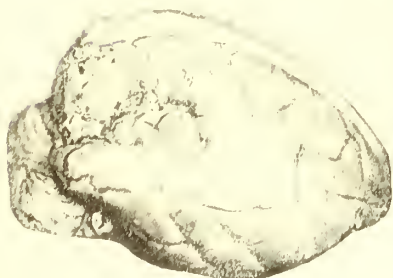

Fig. 21

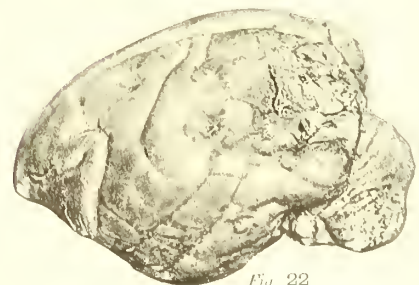

Fig. 22

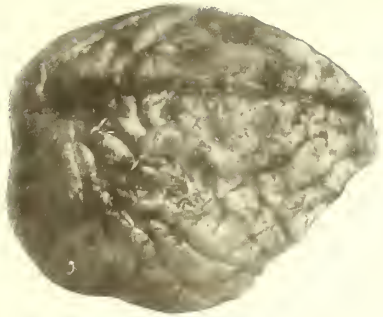


Fig. 39

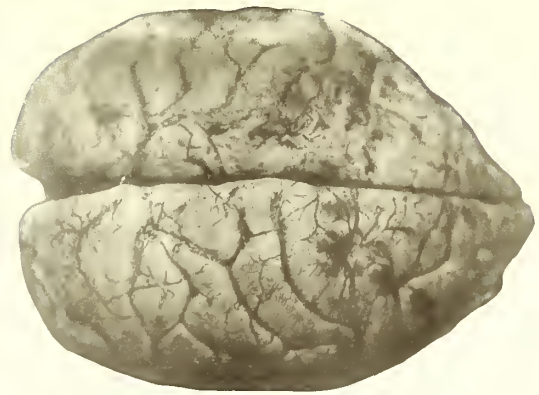


Fig. 40



Fig. 41

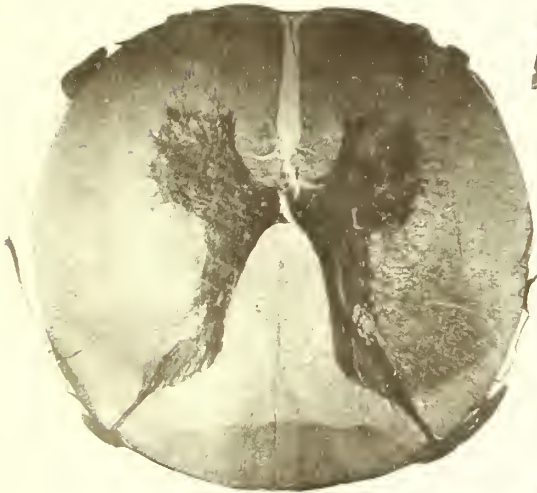

Fig. 42

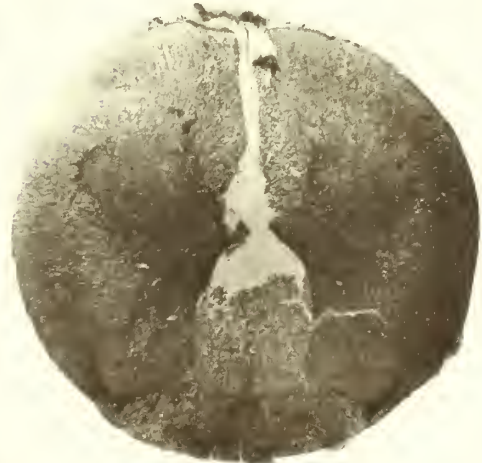

Fig. 44

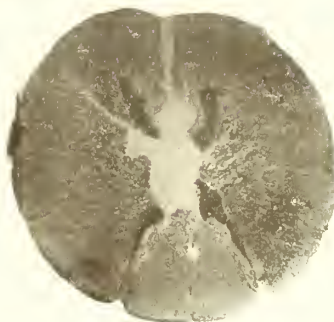


Fig. 43

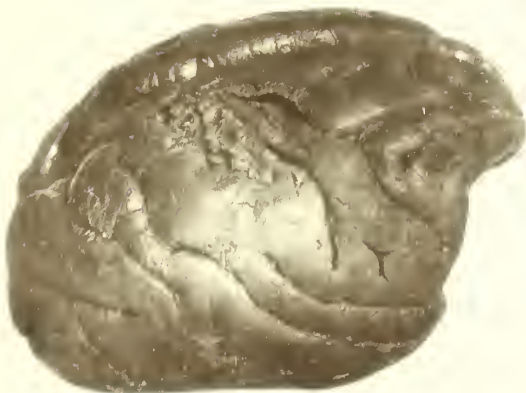


Fig. 45

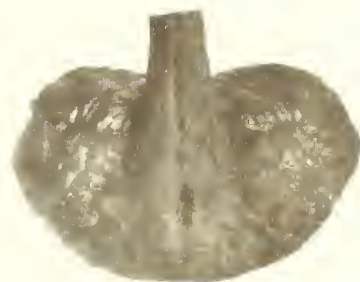

Fig. 46

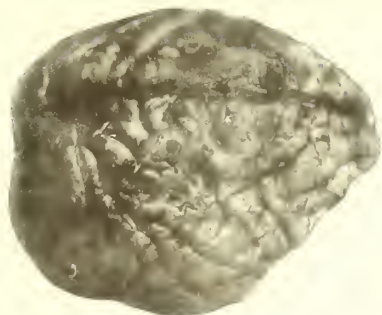


Fig. 39

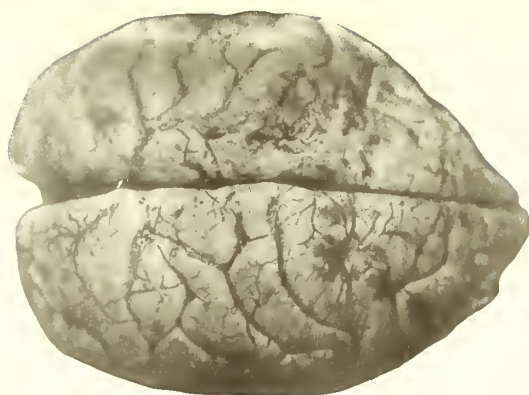


Fig. 40



Fig. 41

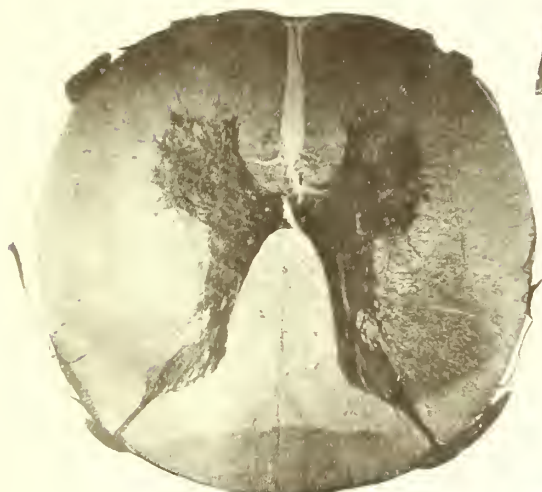


Fig. 42



Fig. 44

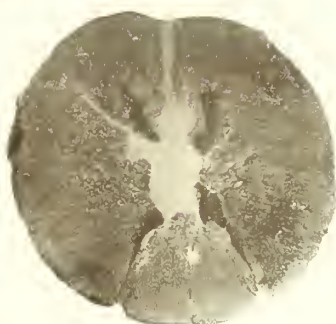


Fig. 43

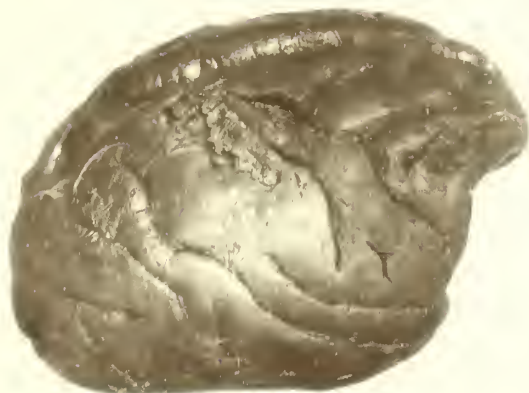

Fig. 45

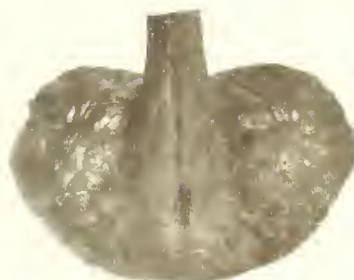

Fig. 46

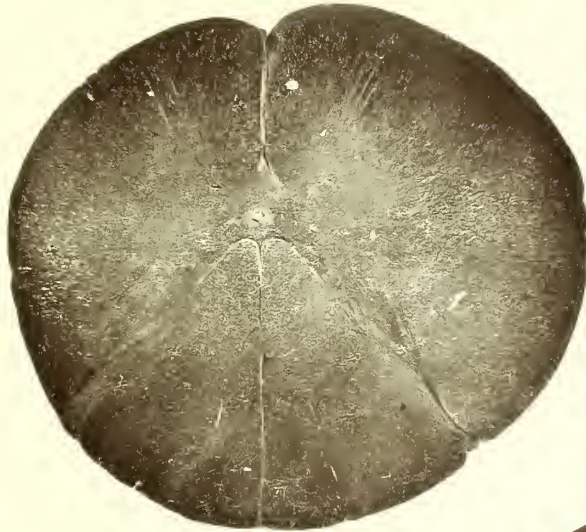

Fig. 49

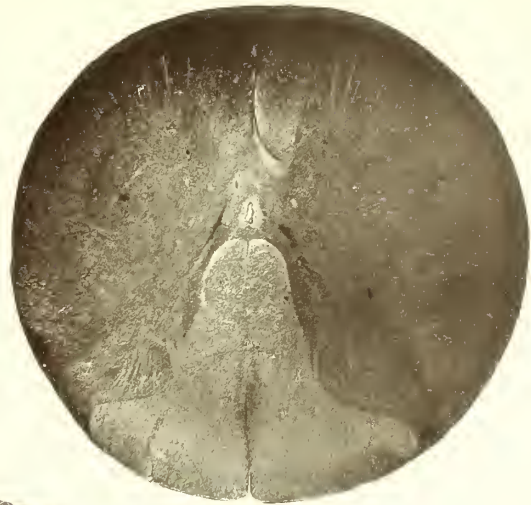

Fig. 51

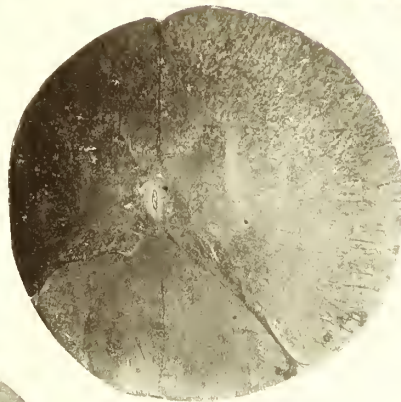


Fig. 50

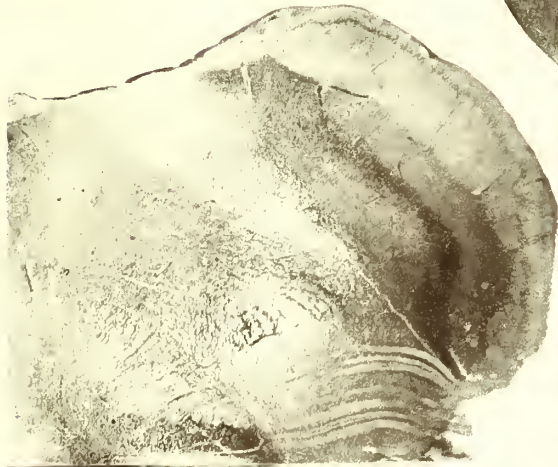

Fig. 47

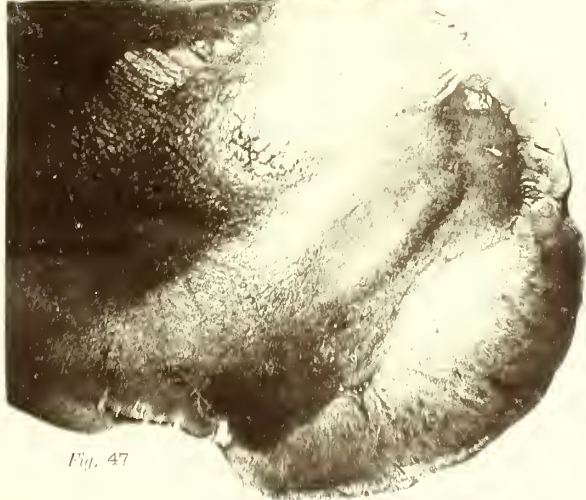


Fig. 48

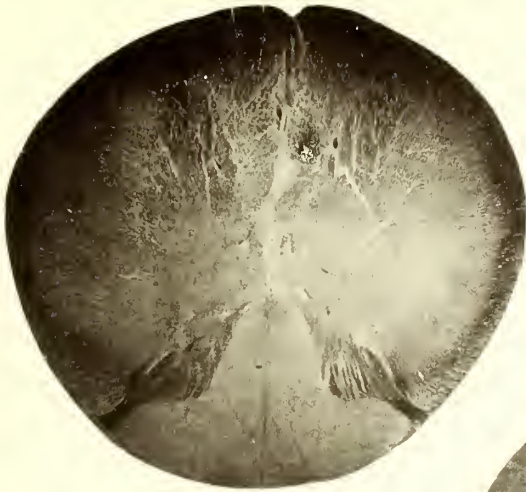

Fig. 53

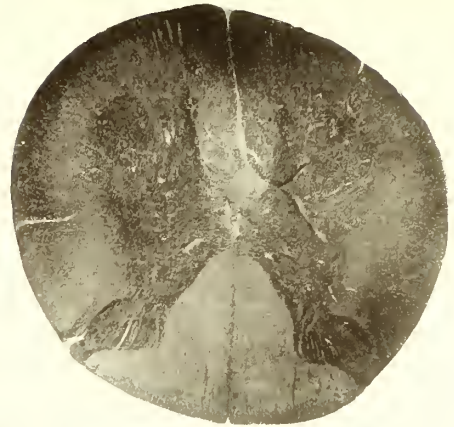


Fig. 55

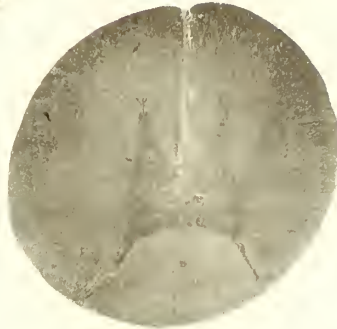


Fig. 54




Fig. 52

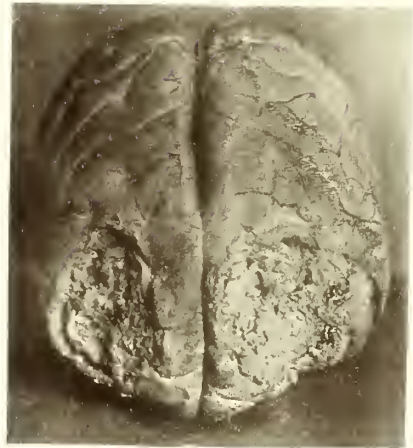

Fig. 56

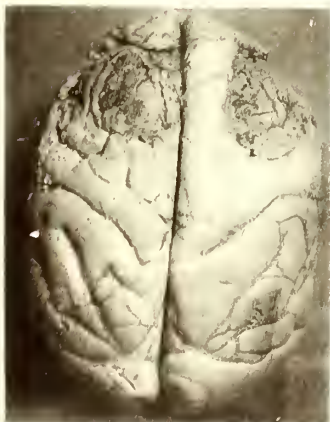

Fig. 57



Fig. 58

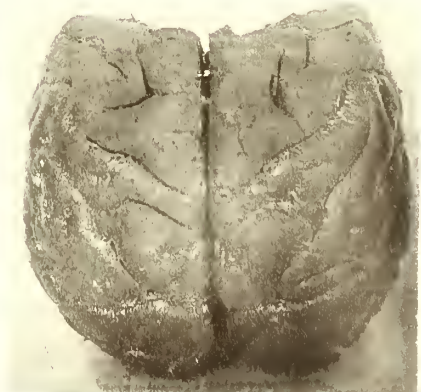


Fig. 59

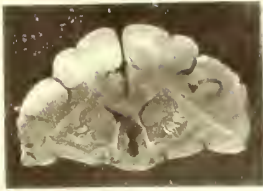


Fig. 61

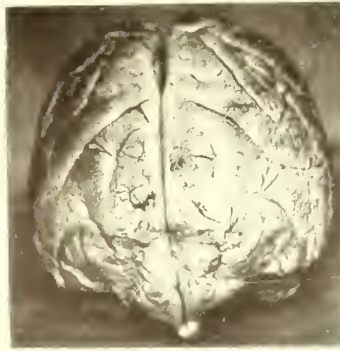


Fig. 60

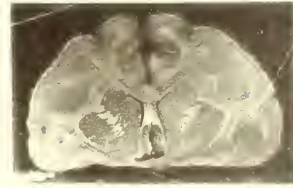


Fig. 62

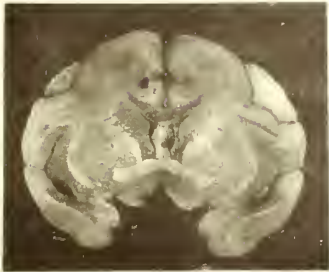


Fig. 63

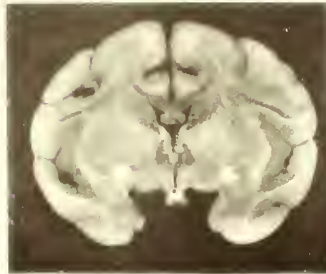


Fig. 64

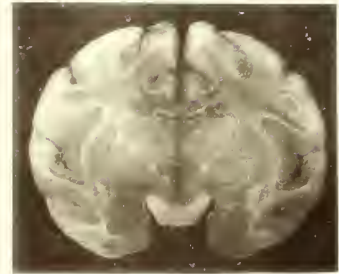


Fig. 65

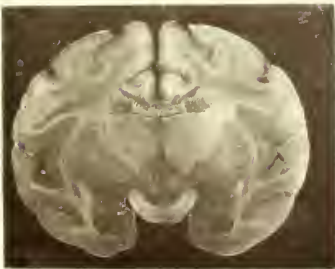

Fig. 66

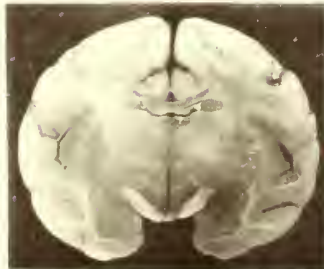


Fig. 67

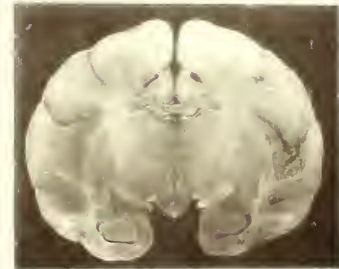


Fig. 68

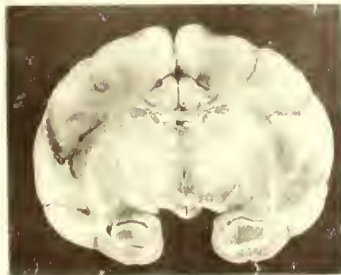


Fig. 69

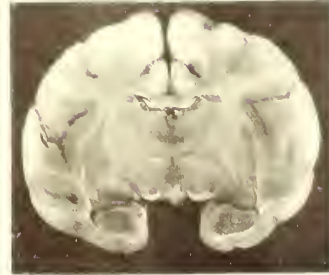


Fig. 70

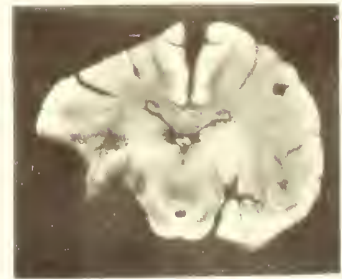


Fig. 71




Fig. 72




Fig. 73

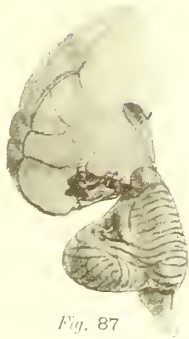

Fig. 87




Fig. 88



Fig. 89

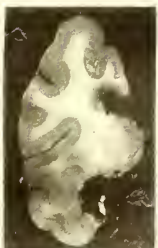

Fig. 90

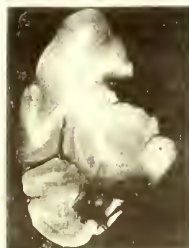

Fig. 91

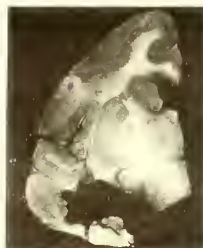


Fig. 92




Fig. 93

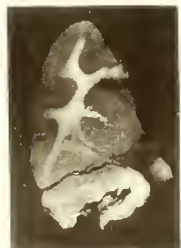


Fig. 94



Fig. 95

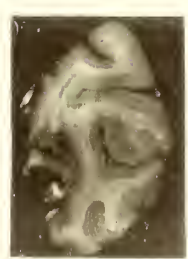

Fig. 97

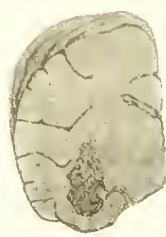


Fig. 96

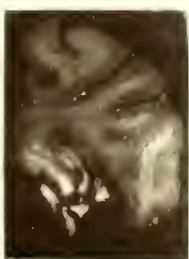


Fig. 98

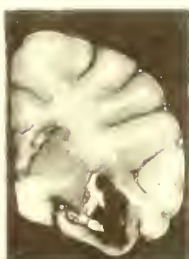

Fig. 99

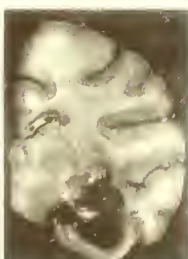


Fig. 100



Fig. 101

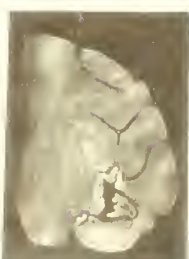

Fig. 103

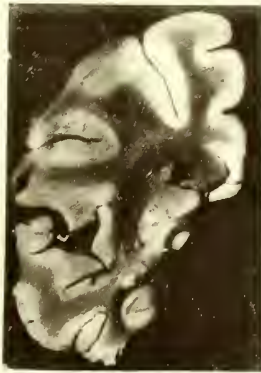


Fig. 104

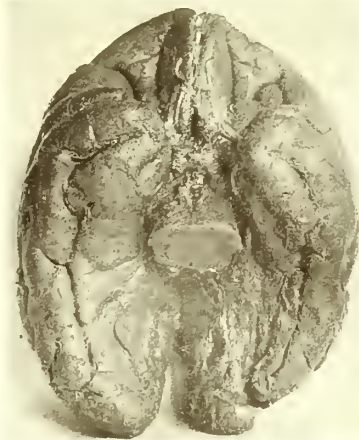

Fig. 103

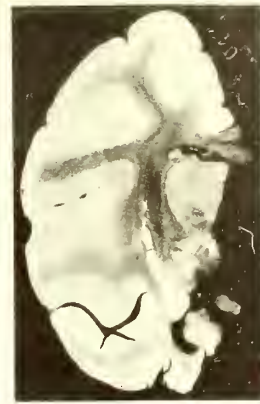


Fig. 105

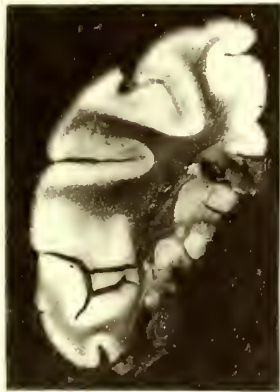

Fig. 106

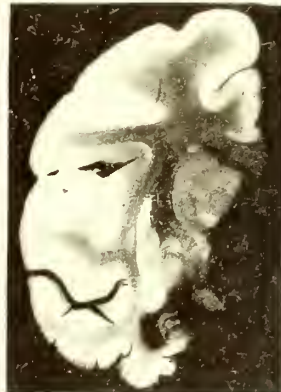

Fig. 107

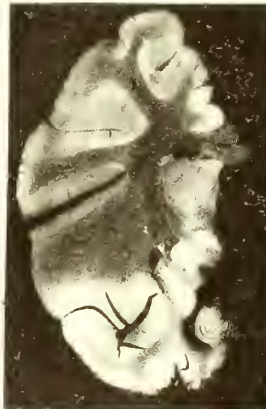


Fig. 108

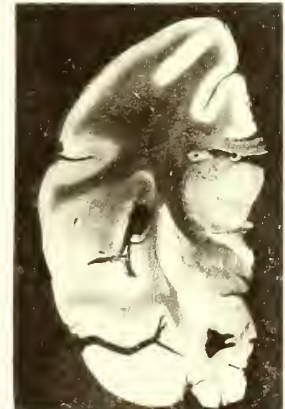

Fig. 109

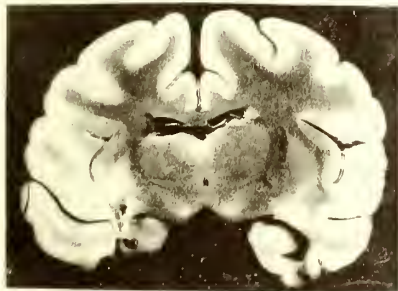


Fig. 111

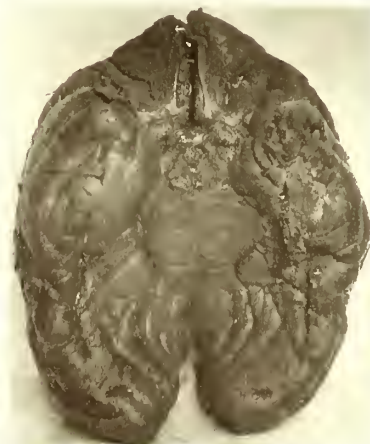

Fig. 110

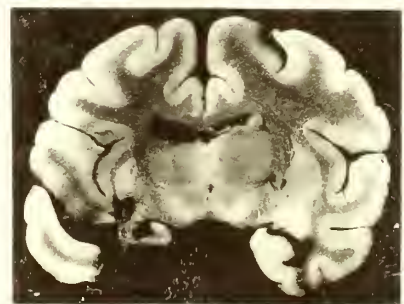


Fig. 112

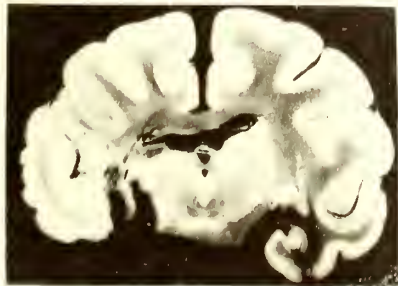


Fig. 113

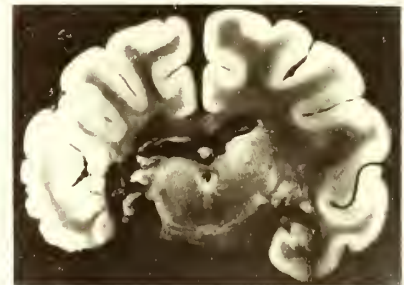


Fig. 114

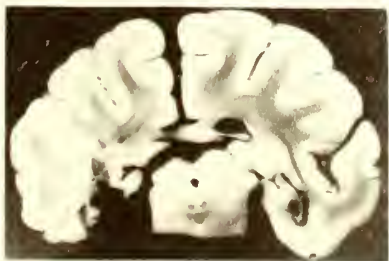


Fig. 115

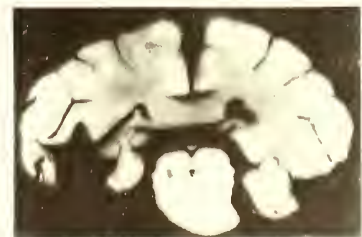


Fig. 116

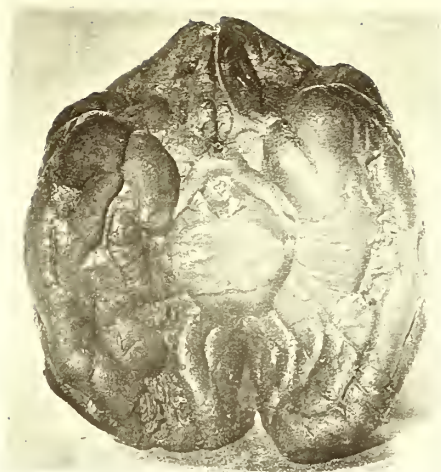

Fig. 117



Fig. 118



Fig. 119



Fig. 120



Fig. 121

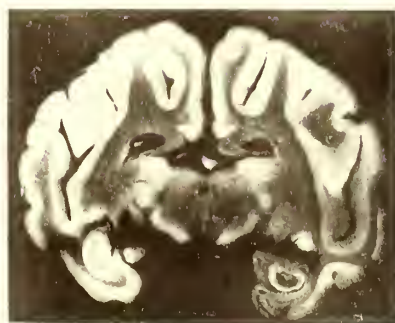


Fig. 122

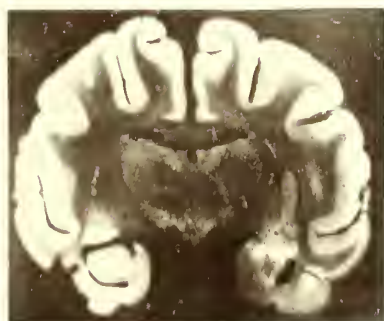


Fig. 123

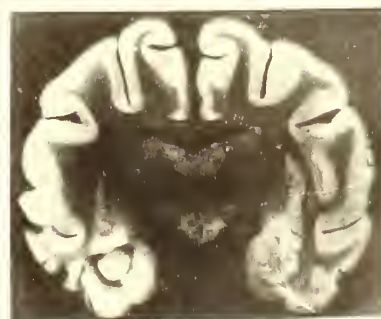


Fig. 124

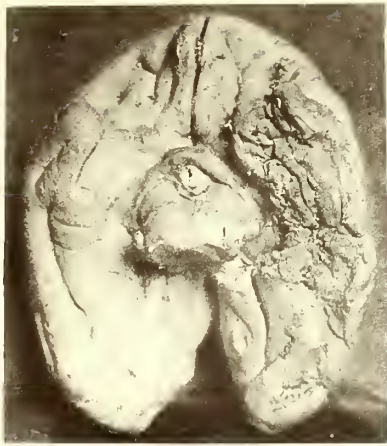

Fig. 125

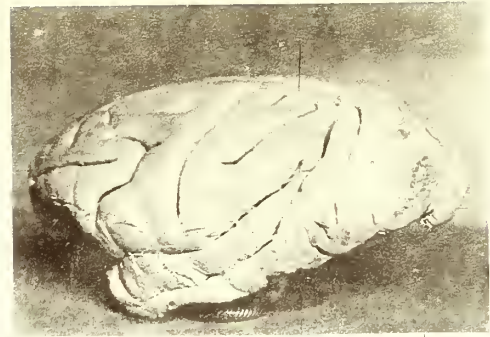


Fig. 126

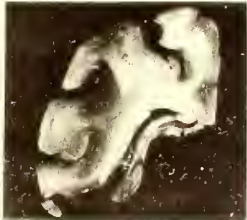


Fig. 127

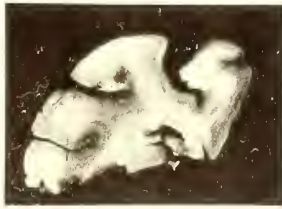

Fig. 128

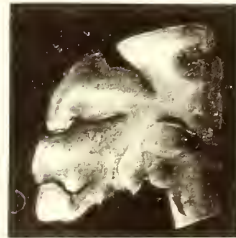


Fig. 129

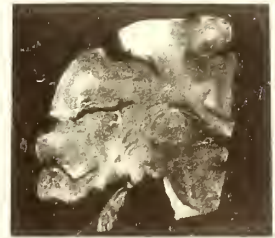


Fig. 130




Fig. 131




Fig. 132

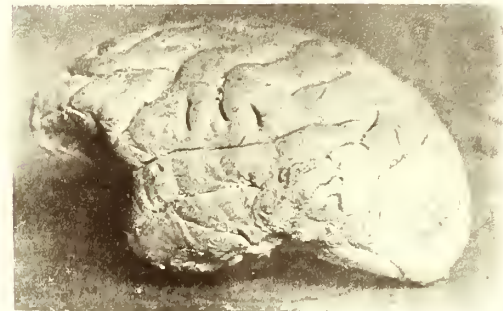

Fig. 133

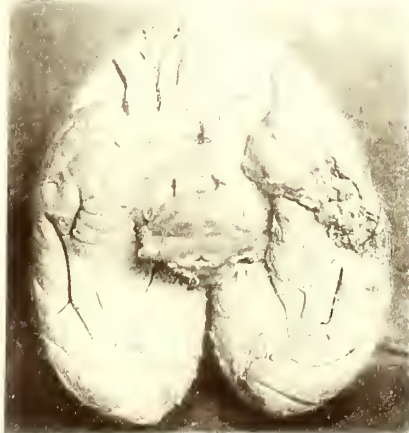

Fig. 134

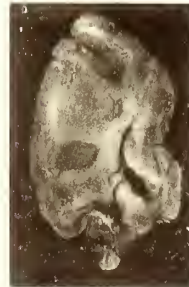


Fig. 135

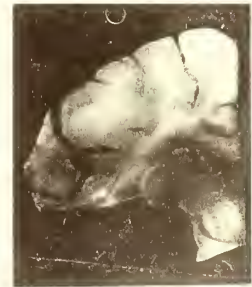

Fig. 136

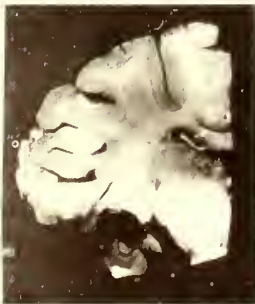


Fig. 137

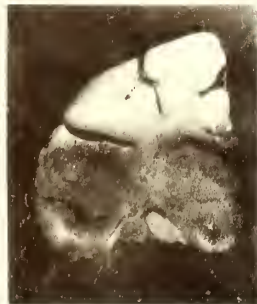

Fig. 138

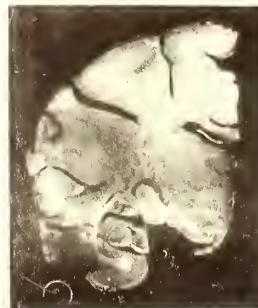

Fig. 139



Fig. 140

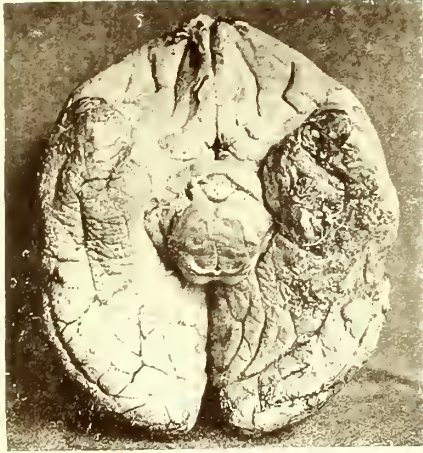


Fig. 141

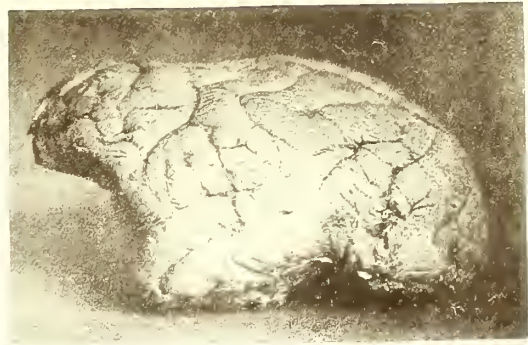


Fig. 142

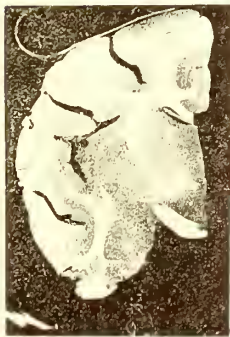

Fig. 143

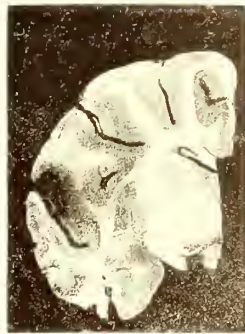

Fig. 144

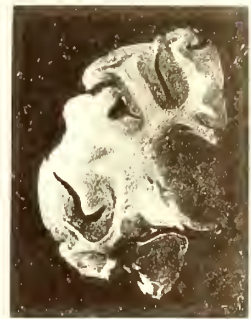

Fig. 145

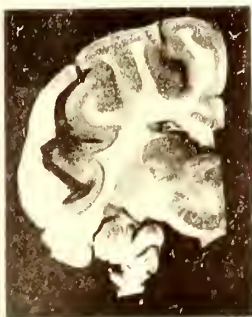


Fig. 146

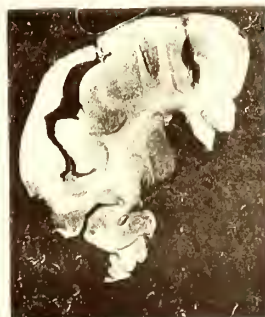

Fig. 147

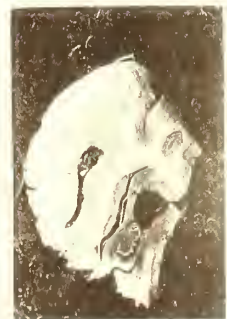

Fig. 148

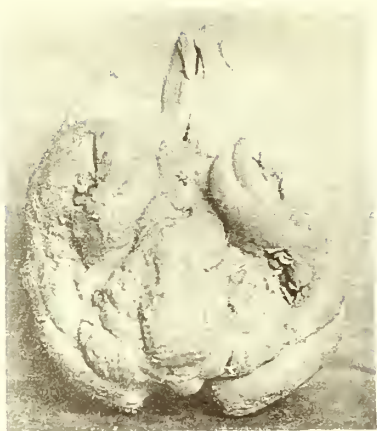

Fig. 149

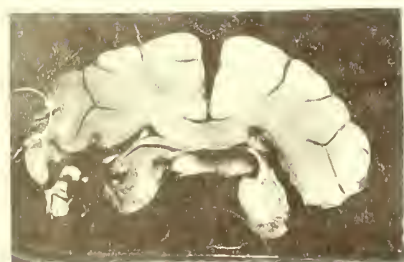

Fig. 150

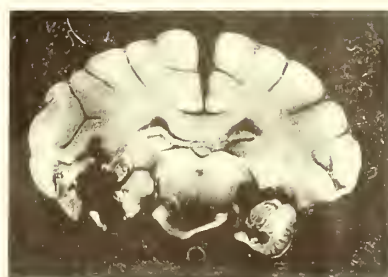


Fig. 151

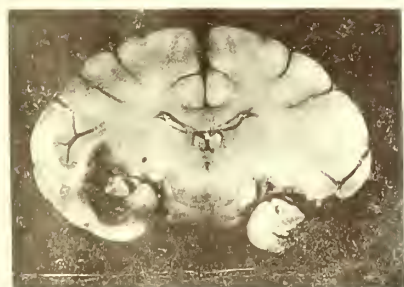

Fig. 152

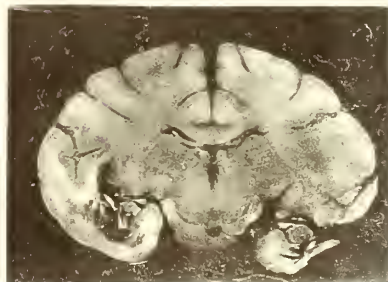


Fig. 153

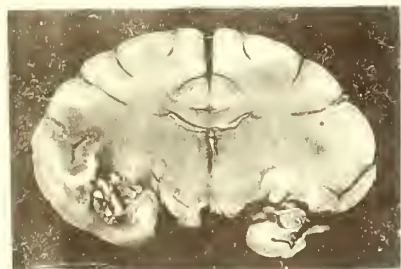


Fig. 154

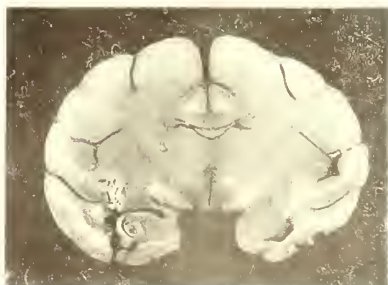

Fig. 155

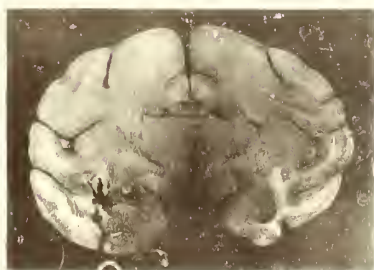


Fig. 156

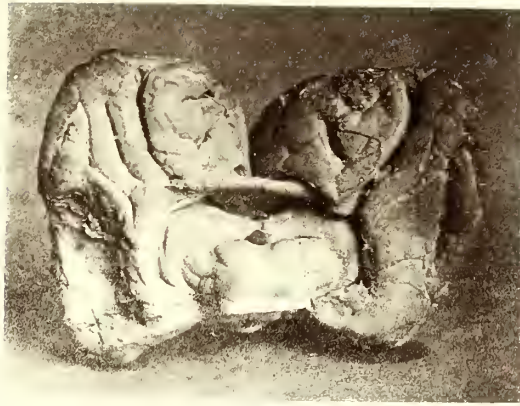

Fig. 157

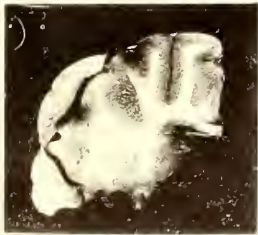


Fig. 158

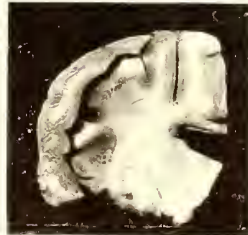


Fig. 159

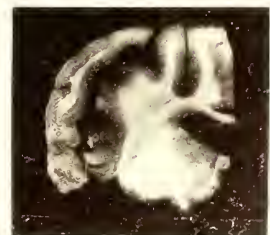

Fig. 160

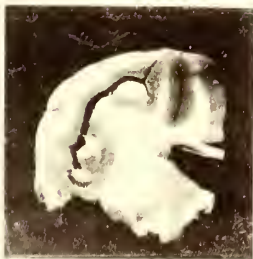

Fig. 161

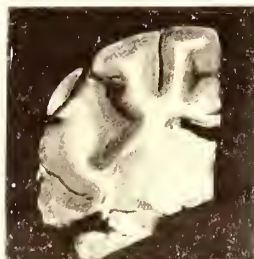

Fig. 162

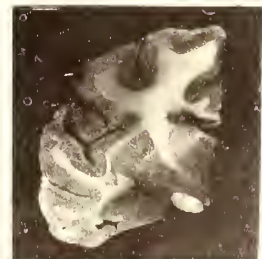


Fig. 163

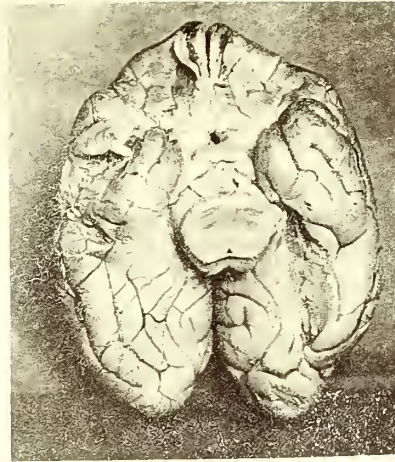


Fig. 164

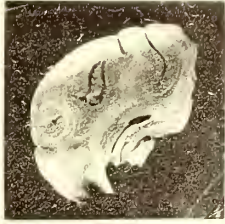


Fig. 165

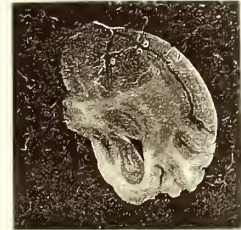


Fig. 166

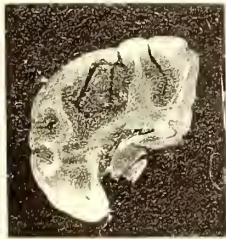


Fig. 167

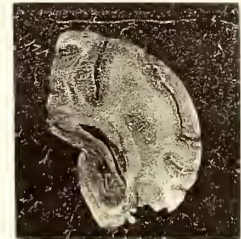

Fig. 168

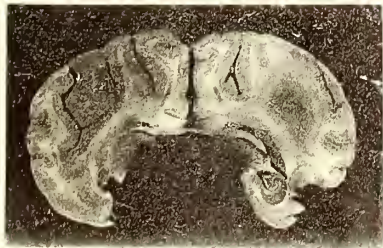


Fig. 169

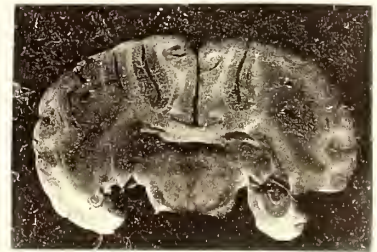

Fig. 170

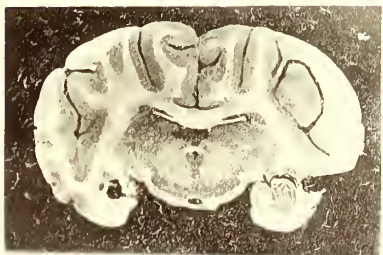


Fig. 171

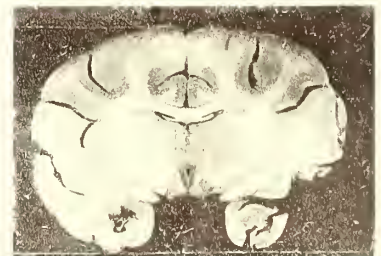


Fig. 172



Fig. 174



Fig. 173

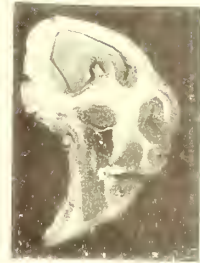


Fig. 175

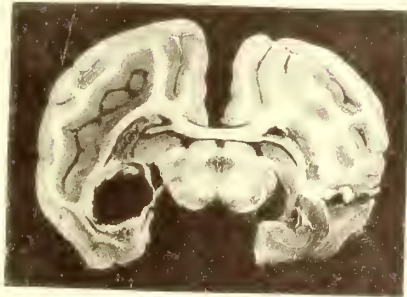


Fig. 176

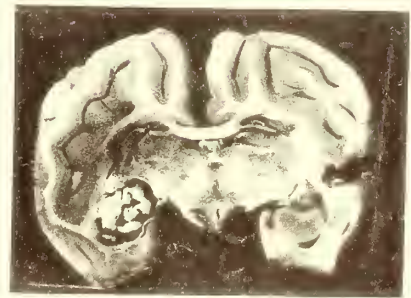


Fig. 177

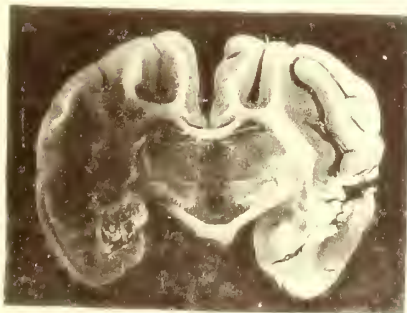

Fig. 178

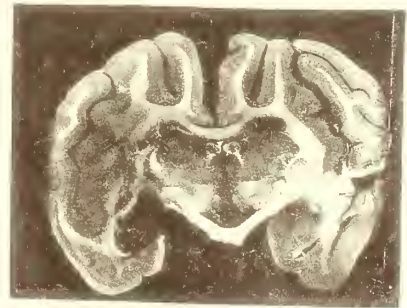


Fig. 179

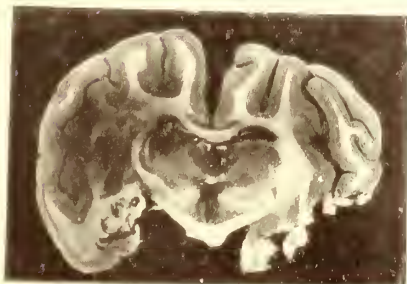


Fig. 180

